

Gynecologic Trauma and Emergencies

Introduction

The current active duty population consists of 14% women, many of whom are subject to the same risks of combat injury as their male colleagues. This chapter deals with OB/GYN emergencies that may present to a deployed medical treatment facility (MTF), particularly in military operations other than war (MOOTW).

Gynecologic Trauma

Vulva

- Vulvar injuries include lacerations and hematomas.
 - **Lacerations** that are superficial, clean, and less than 6 hours old can be primarily closed with absorbable suture. Debridement of obviously devitalized tissue is recommended.
 - ◆ Deep lacerations should be examined and explored to rule out urethral, anal, rectal mucosa, or periclitoral injuries.
 - ◆ Placing a urethral catheter will assist in determining injury. If found, single-layer closure with fine (4-0 or smaller), absorbable suture, leaving the catheter in place, is recommended. Rectal and periclitoral injuries are closed in a similar fashion.
 - ◆ Anal lacerations should be repaired by approximating the cut ends of the anal sphincter with size 0 or 1 absorbable suture.
 - ◆ Antibiotics (2nd generation cephalosporin) are recommended with contaminated wounds.

- Vulvar trauma may cause **infracascial** (below the pelvic diaphragm) **hematoma**.
 - Because the deeper layer of subcutaneous vulvar fascia is not attached anteriorly to the pubic rami, hematoma can spread freely into the anterior abdominal wall.
 - **Most vulvar hematomas are treated conservatively.**
 - **External compression** and ice packs should be applied until hemostasis is ensured by serial examination of the vulva, vagina, and rectum.
 - **Signs of shock in association with a decreasing hematocrit should prompt consideration of extraperitoneal expansion.** Ultrasound or computed tomography is useful for detecting expansion not diagnosed by clinical exam.

A vulvar hematoma continuing to expand despite external pressure, or presenting acutely with a size greater than 10 cm, should be incised and evacuated, with ligation of bleeding vessels and packing placed to secure hemostasis.

Vagina

- Trauma to the vagina can cause **lacerations**, and less commonly, suprafascial (above the pelvic diaphragm) **hematoma**.
- Vaginal trauma has been reported in **approximately 3.5% of women with traumatic pelvic fractures. Concomitant urologic trauma, most often involving the bladder and/or urethra, has been described in about 30% of patients with vaginal trauma.**
- Thorough inspection and palpation of the vagina and rectovaginal exam are necessary for detection of vaginal trauma and to determine the need for further urologic evaluation/imaging. **Due to pelvic instability (in fracture cases) or pain, examination under sedation or anesthesia may be necessary.**
- Patients with vaginal lacerations typically present with bleeding, sometimes profusely, from the well-vascularized vagina.

- Lacerations are repaired using the guidelines given above for vulvar lacerations.
- Vaginal hematoma is usually accompanied by severe rectal pressure and is diagnosed by palpation of a firm, tender mass bulging into the lateral vagina. **Vaginal hematoma should be treated by incision, evacuation, ligation, and packing.**
- Unrecognized vaginal trauma can result in dyspareunia, pelvic abscess, and fistula formation.

Uterus/Cervix

- Trauma to the uterus and cervix is most commonly found in association with pregnancy, but may be seen as a result of penetrating vaginal or abdominal trauma.
- Noninfected simple cervical lacerations should be repaired to optimize restoration of normal anatomy (and possibly decrease the risk of cervical incompetence or stenosis with dysmenorrhea from poor healing). Absorbable 0 grade suture can be used.
- Acute penetrating trauma involving the uterine fundus usually causes little bleeding and can be managed expectantly without repair. Damage to the uterine wall with bleeding can be repaired with size 0 absorbable suture.
- **Trauma involving the lateral wall of the uterus may cause significant bleeding**, but can usually be controlled by successive ligation of the ascending and descending branches of the uterine artery as described below in the obstetrical section “uterine atony.”

Hemorrhage not responding to ligation, or extensive mutilating damage to the cervix or uterus, is best treated by hysterectomy.

- Prophylactic antibiotics should be given. **Adnexa should be retained unless there is an indication for removal** (see next page).

Basic steps for performing an emergent total abdominal hysterectomy.

- Ligate/cauterize round ligaments (Fig. 19-1).
- Incise anterior leaves of broad ligaments bilaterally, then continue across midline to incise vesicouterine fold.
- Mobilize bladder downward by blunt dissection (and sharp dissection if necessary) from lower uterine segment and cervix.*
- To **retain** adnexa, clamp/cut/ligate utero-ovarian ligaments and fallopian tubes near their connections to uterine fundus (Fig. 19-2).
- To **remove** adnexa with uterus, clamp/cut/ligate infundibulopelvic ligaments after making windows in posterior leaves of broad ligaments above ureters.
- Incise posterior peritoneum to mobilize adnexa either away from (if being retained) or toward (if being removed) uterus.
- Incise peritoneum overlying rectovaginal space, then mobilize rectum downward and away from posterior vagina by blunt dissection (Fig. 19-3).*
- Clamp/cut/ligate uterine arteries along lateral surface of uterus at uterocervical junction, staying within 1 cm of uterus to avoid damaging ureters.
- Clamp/cut/ligate remainder of cardinal ligaments, paracervical tissue, and uterosacral ligaments by taking successive inferior bites until cervicovaginal junction is reached; each bite should be placed medial to previous bite to avoid injuring ureter and bladder.
- Crossclamp vagina below cervix.
- Transect vagina, removing uterus (and attached adnexa, if applicable).
- Suture vaginal cuff closed, ensuring bladder is not incorporated.

*In case of dense adhesions between cervix and bladder or rectum in emergent setting, or ongoing hemorrhage with poor visualization, supracervical hysterectomy can be performed. After mobilizing bladder and rectum from uterus and ligating uterine arteries, uterine fundus is transected from cervix with a knife. Cervix is then oversewn with a baseball stitch, staying medial to ligated uterine arteries.

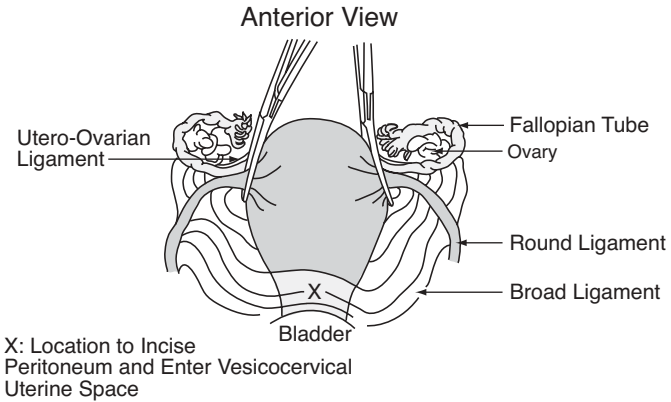


Fig. 19-1. Abdominal hysterectomy anterior view.

Adnexa

● Fallopian Tubes.

- o Damage to the wall of the fallopian tube by ruptured ectopic pregnancy or penetrating abdominal trauma should be treated by salpingectomy if there is significant damage to the tube, due to the risk of subsequent or recurrent ectopic pregnancy if left in situ. If the damage is

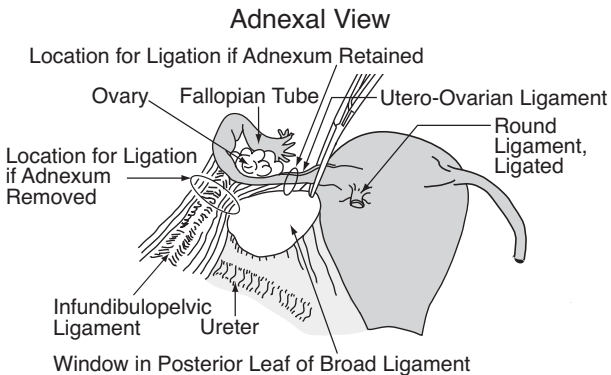


Fig. 19-2. Abdominal hysterectomy adnexal view.

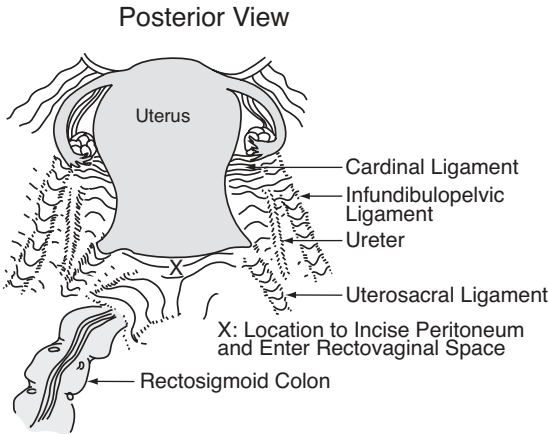


Fig. 19-3. Abdominal hysterectomy posterior view.

equivalent to a linear salpingotomy (see below), achieve hemostasis, then allow healing by secondary intention.

- o The mesosalpinx is ligated or cauterized, then the tube ligated and cut at its connection with the uterine fundus.
- o Unruptured ampullary /isthmic ectopic pregnancy can be treated by linear salpingotomy, with extraction of the ectopic gestation. The tubal incision is left open to heal by secondary intention.
- o An unruptured or ruptured cornual/interstitial ectopic pregnancy requires wedge resection of the uterine cornuum with salpingectomy.
- o An ectopic pregnancy spontaneously aborted into the abdominal cavity through the end of the tube should be removed, but the tube may be left in situ if hemostasis is attained.

● **Ovaries.**

- o A **ruptured ovarian cyst** should be treated via cystectomy by shelling the cyst wall out of the ovary, then cauterizing or ligating any bleeding vessels, usually at the base of the cyst.

- o **Torsion of an ovarian mass** is first treated by assessing the ovary. Untwist the ovary and or fallopian tube. If it appears healthy with some continuing blood supply, it can be left in situ. If the ovary contains a large (> 4 cm) simple appearing cyst, the cyst can be drained and the cyst wall removed. Interrupted sutures using a fine monofilament or electrocautery can be used to obtain hemostasis. If the ovary appears dark and dusky after untwisting, perform a salpingo-oophorectomy by ligating the infundibulopelvic ligament first (after identifying the ureter), then the utero-ovarian ligament and fallopian tube.
- o Hemorrhage from an infundibulopelvic ligament, as a result of penetrating abdominal trauma, is best treated by ligation with salpingo-oophorectomy.

Retroperitoneal Hematoma

- **Laceration of an arterial branch of the hypogastric artery can cause a retroperitoneal hematoma.**
- A large amount of blood may collect in the broad ligament with few symptoms. Dissection of the hematoma can extend up to the level of the renal vessels. The hematoma may be discovered during emergency surgery for trauma or during re-operation or post pelvic surgery, or can be prompted by signs of shock suggesting internal bleeding.
- Retroperitoneal hematoma can be treated by hypogastric artery ligation on the affected side. **Bilateral hypogastric artery ligation may be necessary for hemostasis.** The uterus, tubes and ovaries may be left in situ if viable and without other indication for removal.

Gynecologic/Obstetric Emergencies

- **Acute Vaginal Hemorrhage Unrelated to Trauma.**
 - o **Bright red vaginal bleeding filling more than one large perineal pad per hour is considered vaginal hemorrhage.** A pregnancy test and pelvic exam direct initial therapy.
 - ◆ **If the patient is not pregnant,** hormonal management with 25 mg IV Premarin or 50 mcg estrogen-containing oral birth control pills (OCPs) should be given every 6 hours.

- ◇ If the bleeding responds to hormonal management, OCPs should be continued qid for 5–7 days while more definitive diagnosis and management plans are made.
- ◇ If the bleeding has not decreased significantly within 24 hours, dilatation and curettage is reasonable. If the heavy bleeding continues, imaging studies and possibly coagulation studies will be needed to help direct further therapy.
- ◆ **In the pregnant patient**, heavy bleeding from the cervical os with uterine size < 20 weeks (fundus at/or below the level of patient's umbilicus) suggests spontaneous abortion. Dilatation and suction curettage should be performed.
 - ◇ Ectopic pregnancy uncommonly presents with acute hemorrhage, but should be considered if the patient has an acute abdomen or if scant tissue is obtained on curettage.
 - ◇ In a pregnant patient with uterine size consistent with a third trimester gestation (> 4 cm above the umbilicus in a singleton pregnancy), vaginal hemorrhage is usually an indication of placental abruption or placenta previa.
 - ◇ Emergent cesarean section will be necessary if the uterine hemorrhage does not spontaneously resolve within several minutes.
 - ◇ After delivery of the fetus and placenta, persistent hemorrhage unresponsive to more conservative measures may require hysterectomy (see **emergent cesarean** and **uterine atony** below).
 - ◇ Pregnant patients (mothers) with acute vaginal hemorrhage who have Rh negative bloodtype, or if their Rh status is unknown, should be given RhoGAM 300 mcg IM.
- **A hemorrhaging mass in the vagina is most likely cervical cancer.** The vagina should be packed to tamponade the bleeding after placing a urethral catheter. Placing sutures is generally futile and may make the bleeding worse.

Precipitous Vaginal Delivery

● **Preparation.**

- Supplies needed for the delivery, include povidone-iodine sponges, a 10 cc syringe, lidocaine, 2 Kelly clamps, ring forceps, dry towels, a bulb syringe, and scissors.
- The mother should be placed on her left side for labor.
- The fetal heart rate should be determined every 15 minutes prior to pushing, and following each contraction during the pushing phase using a vascular Doppler. **Normal heart rate is between 120–160 bpm.** The heart rate often drops with the contraction, but should recover to normal prior to the next contraction.

If the heart rate drops below 100 and stays low for more than 2 minutes, a cesarean section should be considered.

- When the patient presents, the cervix should be examined to determine dilation and fetal position. For the woman to begin pushing, the cervix should be completely dilated (10 cm) and no cervix should be felt on either side of the fetal head. If the baby's head is not presenting, move to cesarean section immediately. If there is any question, and ultrasound is available, it should be used to determine the presentation.
- **Delivery.**
 - Once the patient begins pushing, flex the hips to optimally open the pelvis. The patient may be on her back, or tilted slightly to the left. Assistants should support the legs during pushing and relax them between contractions.
 - Clean the perineum with sterile Betadine solution. If this is the patient's first delivery, the perineum should be anesthetized with lidocaine in case an episiotomy is needed. There is little support for prophylactic episiotomy, but may be necessary if the fetus is large, or tearing is anticipated.
 - The fetal head delivers by extension. Pushing upward on the fetal chin through the perineum can assist this process.

Additionally, it is extremely important to control the rate of delivery of the head with the opposite hand.

- o If an episiotomy is needed, it should be cut in the posterior midline from the vaginal opening approximately $\frac{1}{2}$ the length of the perineum, and extend about 2–3 cm into the vagina.
 - o After delivery of the head, the mouth and nose should be suctioned and the neck palpated for evidence of a nuchal cord. If present, this should be reduced by looping it over the fetal head, or by clamping twice and cutting if it will not reduce.
 - o Next, the operator's hands are placed along the parietal bones and the patient is asked to push again to allow delivery of the anterior shoulder. Gentle downward traction should allow the shoulder to clear the pubis, and the fetus should be directed anteriorly to allow delivery of the posterior shoulder. The remainder of the body will normally follow rapidly. Wrap infant in dry towels.
 - o Once the fetus delivers, the cord should be doubly clamped and cut. The placenta usually delivers within 15 minutes of delivery, but may take up to 60 minutes. Delivery of the placenta is heralded by uterine fundal elevation, lengthening of the cord, and a gush of blood. While waiting, gentle pressure may be placed on the cord, however, vigorous uterine massage and excessive traction can lead to complications.
 - o Following delivery of the placenta, the patient should be started on an infusion of lactated Ringers with 20 units of oxytocin (Pitocin). Oxytocin can also be given IM if there is no IV access. If there is no oxytocin available, alternatives are methylergonovine maleate (Methergine) 0.2 mg intramuscular (IM) or allowing the patient to breastfeed.
The placenta should be inspected for evidence of fragmentation that can indicate retained products of conception.
- **Inspection and repair.**
 - o Following delivery of the placenta, the vagina and cervix should be inspected for lacerations. Downward digital pressure on the posterior vagina and fundal pressure (by

an assistant, if available) will facilitate visualization of the cervix. A ring forceps is then used to grasp and visualize the entire cervix.

- o The vagina should be inspected with special attention to the posterior fornix. The perineum and periurethral areas should also be inspected. Vaginal and cervical lacerations may be repaired with 3-0 vicryl or an equivalent suture in running or interrupted layers.
- o If the anal sphincter is lacerated, it should be reapproximated with 2-0 absorbable interrupted single or figure-of-eight sutures.
- o If the patient has torn into the rectum, the rectal-vaginal septum should be repaired with interrupted sutures of 3-0 vicryl. A second layer imbricating the underlying tissue will decrease the risk of breakdown. Care should be taken to preserve aseptic technique. If a large tear is noted, a saddle block or spinal anesthetic may be necessary.
- o Patients with a periurethral tear may require urethral catheterization. In addition to lacerations, hematoma in the vulva, vagina, or retroperitoneum may occur. See above gynecologic trauma for management.

Emergency Cesarean Section

- Indications.
 - o Fetal heart rate drops below 100 and stays down for more than 2 minutes.
 - o Acute uterine hemorrhage persisting for more than a few minutes (suggestive of placental abruption or previa).
 - o Breech or transverse fetal presentation.
- The patient should be placed in the left tilt position with an IV bag or towel displacing the uterus to the left. She should undergo a quick prep from just below the breasts to the mid thigh. A major abdominal equipment set should have most of the instruments that you will need.
- **Basic steps to performing an emergency C-section** (Fig. 19-4 a,b,c,d).
 - o Enter the abdomen through lower midline.

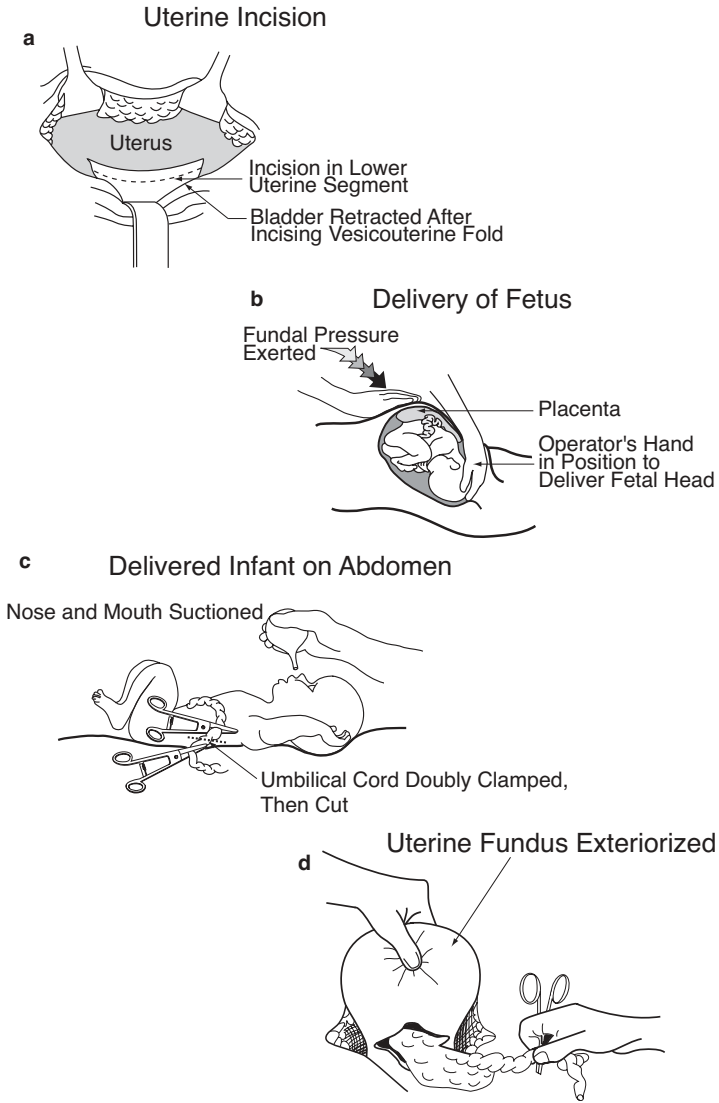


Fig. 19-4. Emergency C-Section.

- o Identify and incise the peritoneal reflection of the bladder transversely, and create a bladder flap to retract the bladder out of the field.
- o Using a scalpel, carefully incise the uterus transversely across the lower uterine segment (where the uterine wall thins).
- o Once the amniotic membranes are visible or opened, extend the incision laterally, either bluntly or by **carefully** using bandage scissors. **Avoid the uterine vessels laterally.** If necessary, the incision can be extended at one or both of its lateral margins in a J-fashion by vertical incision.
- o Elevate the presenting fetal part into the incision, with an assistant providing fundal pressure.
- o Upon delivery of the fetus, suction the nose and mouth and clamp and cut the cord. Hand the infant off for care (see below).
- o Direct anesthetist to administer 2 grams of cefazolin (Ancef) once the cord is clamped.
- o Allow the placenta to deliver by providing gentle traction on the cord and performing uterine massage.
- o Begin oxytocin, if available as above.
- o Using a sponge, clean the inside of the uterus, and vigorously massage the fundus to help the uterus contract.
- o Quickly close the incision with 0-vicryl. A single layer (running, locking) is adequate, if hemostatic, for transverse incisions. Take care to avoid the lateral vessels. If the incision has a vertical extension, close it in 2 or 3 layers.
- o Once hemostasis is assured, close the fascia and abdomen in the usual fashion.
- o In the rare case of continued uterine hemorrhage, evaluate and treat as outlined in the section below.

Uterine Atony

- The majority of postpartum hemorrhage is secondary to uterine atony (failure of uterine contracture).

When the uterus fails to contract following delivery of the placenta, bleeding may be torrential and fatal.

- Initial management should include manual uterine exploration for retained placenta. Without anesthesia, this procedure is painful. An opened sponge is placed around the examiner's fingers. Place the opposite hand on the patient's uterine fundus and apply downward pressure. Gently guide your fingers through the open cervix and palpate for retained placenta. The inside of the uterus should feel smooth, and retained placenta will feel like a soft mass of tissue. This may be removed manually or by using a large curette if available.
- If no tissue is encountered, use both hands to apply vigorous uterine massage to improve the uterine tone.
- Medications should also be used if available. Oxytocin may be given by IV bolus using 40 units in 1000 cc, or up to 10 units IM, but never by IV push. Although unlikely to be available, other medications that can be considered are Methergine, dinoprostone (Prostin), and misoprostol (Cytotec).
- If no medication is available, the patient should be encouraged to breast feed or do nipple stimulation to increase endogenous oxytocin release.

If conservative measures fail to arrest the postpartum hemorrhage, laparotomy (if the hemorrhage is occurring post vaginal delivery), should be performed.

- Intraoperative massage of the uterine fundus may be tried.
- **If the massage fails to improve uterine tone, the uterine arteries should be ligated in a stepwise fashion.** Begin with the ascending branch at the junction of the upper and lower uterine segment. Using 0 or No. 1 chromic, place a stitch through the myometrium medial to the artery from front to back. The stitch is then brought out through the adjacent broad ligament and tied. If bilateral ligation of the ascending branch does not control bleeding, the descending branch should be ligated at the level of the uterosacral ligament. **If this fails, consider bilateral hypogastric artery ligation (see above). If this fails, proceed to hysterectomy** as outlined in the gynecologic portion of this chapter.

Neonatal Resuscitation

- **Immediately following delivery, every infant should be assessed for need for resuscitation.** Equipment that may be needed includes warm towels, bulb syringe, stethoscope, flow-inflating or self-inflating bag with oxygen source, laryngoscope and blade, suction catheter, and endotracheal tube. The two medications that may be needed are epinephrine 1:10,000 and naloxone (Narcan) 0.4 mg/ml.
- Nearly 90% of term babies are delivered without risk factors and with clear fluid, requiring only to be dried, suctioned and observed. **If the baby is less than 36 weeks, or if there is meconium in the fluid at delivery, the baby will need to be observed more closely.**
 - In the first 30 seconds after delivery, dry and stimulate the baby, position it in order to open the airway, and give free flow oxygen if the color is poor.
 - At 30 seconds, evaluate the heart rate. **If it is < 100 begin to provide positive pressure ventilation.** After 30 seconds of ventilation, recheck the heart rate. **If it is < 60, then chest compressions should be started.** After 30 seconds of chest compressions, again re-evaluate. If the heart rate remains < 60 you should administer epinephrine. Epinephrine can be given either through the umbilical vein or the endotracheal tube. The level of experience of the team present should dictate which route should be used. The dose is 0.1–0.3 ml/kg of the 1:10,000 solution.
 - If heart rate rises over 100, stop the positive pressure ventilations, but continue to provide free flow oxygen. If the mother has been given a dose of narcotics in the 4 hours prior to delivery, and positive pressure ventilation has resulted in a normal heart rate and color but poor respiratory effort, then naloxene is indicated. Administer naloxene by IV, IM, or endotracheal route at a dosage of 0.1 mg/kg.
- If at any time during resuscitation the heart rate goes above 100, with good respiratory effort, tone and color, the baby may be moved to an observation status.

