

Vascular Injuries

Introduction

- History.
 - World War II: Popliteal artery injuries were routinely ligated with a 73% amputation rate.
 - Korean War: Formal repair of peripheral arterial injuries instituted.
 - Vietnam War: Further refinements in arterial repair; amputation rate for popliteal artery injuries is reduced to 32%.
- There are various types of wounds seen in combat.
 - Low-velocity missile damages a blood vessel lying directly in its path.
 - High-velocity missile blast effect causes fragmentation of the missile or bone and widespread destruction, including vascular injury at a distance.
 - Blunt trauma, often resulting from sudden deceleration in motor vehicle accidents, falls, rail and air disasters.
 - Popliteal artery injury associated with posterior knee dislocations.

Evaluation and Diagnosis

- Physical examination — detailed examination is paramount.
 - **Hard signs of arterial injury** (pulsatile external bleeding, enlarging hematoma, absent distal pulses, a thrill/bruit, or ischemic limb) should lead to **immediate surgical exploration, without further preoperative studies**.
 - ◆ The 6 Ps of acute ischemia are: pain, pallor, pulselessness, poikilothermia, paresthesia, and paralysis.
 - ◆ Degree of injury and adequacy of collateral flow will determine the severity of distal ischemia. **Remember: Warm ischemia of striated muscle for > 4–6 hours will likely lead to myonecrosis and major amputation.**

- ◆ Falsely attributing loss of pulse, diminished pulse, or asymmetry of pulses to arterial spasm may cause delay in detection/repair of limb-threatening arterial injury.
- ◆ Distal pulses may be intact in up to 20% of patients with arterial injuries.
- **Soft signs** of arterial injury that require additional diagnostic evaluation include proximity of wound to major vessels, history of hemorrhage/shock, nonexpanding hematoma, diminished pulse, and anatomically related nerve injury.
- Doppler examination.
 - A patient with penetrating or blunt trauma who has a normal distal pulse exam and ankle-brachial index (ABI) ≥ 1.0 does not require arteriography.
 - In the patient without a palpable pulse distal to the injury, perform a Doppler examination and an ABI. ABI < 0.9 or a difference in ABI between extremities of > 0.1 indicate an arterial injury until proven otherwise. Because of extensive collateral flow, injuries to the deep femoral or deep brachial artery are not ruled out by this technique.
- Duplex ultrasound (US).
 - Color flow duplex ultrasonography has demonstrated high sensitivity and specificity for detecting arterial injuries. It is noninvasive, portable, and painless, and repeated exams are easily performed.
 - Duplex is highly operator-dependent and may fail to detect all arterial injuries (eg, deep femoral or tibial injuries).
- Contrast angiography.
 - Precise localization of vascular injury is useful in patients with multiple pellet wounds (eg, shotgun blast), fractures, and penetrating injuries to the neck and thoracic outlet.
 - Consider with high-velocity wounds, where arterial injury may occur outside the path of the missile, or in the presence of soft signs of arterial injury.
 - Consider as routine for knee dislocations where occult arterial injuries may occur, and undetected delayed popliteal artery thrombosis may lead to major amputation.

Management Aspects

- Initial management.
 - **Control external bleeding immediately!** Blind or imprecise placement of vascular clamps in a bloody field is discouraged. Direct pressure to the bleeding wound is preferable; **temporary tourniquet (BP cuff)** placed proximal to the injury site and inflated above systolic blood pressure may be useful.
 - Administer IV antibiotics, tetanus toxoid, and analgesia.
 - **In most long-bone fractures**, resuscitation and fracture alignment will restore distal flow.
 - **Indications for operation for a suspected vascular injury:**
 - ◆ Hard signs as discussed above.
 - ◆ Soft signs confirmed by duplex US and/or angiography.
- Operative management.
 - Preparation and draping of injured extremity as well as contralateral uninjured lower or upper extremity in case repair requires autogenous vein graft.
 - Surgical approaches to the femoral popliteal, and brachial arteries are shown in Figures 27-1–Figure 27-5.

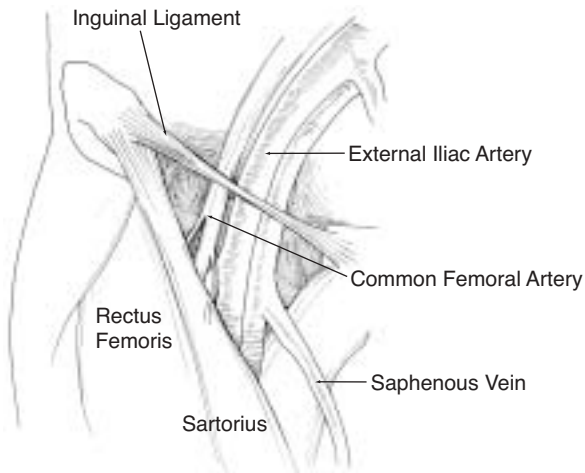


Fig. 27-1. Inguinal anatomy.

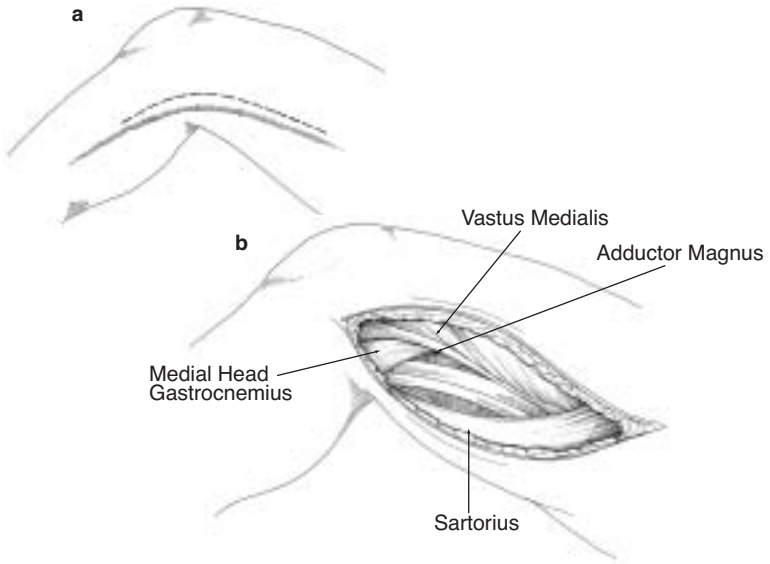


Fig. 27-2. Exposure of distal femoral and popliteal vessels.

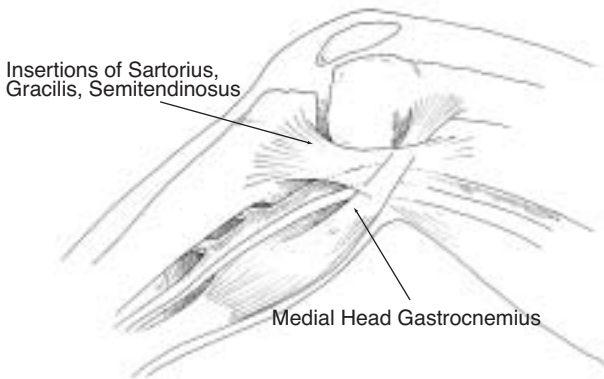


Fig. 27-3. Medial approach to popliteal vessels.

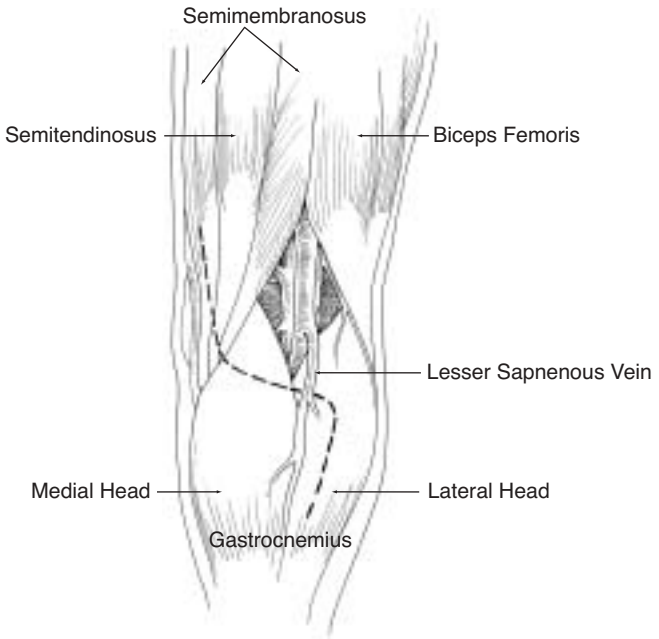


Fig. 27-4. Posterior approach to popliteal vessels.

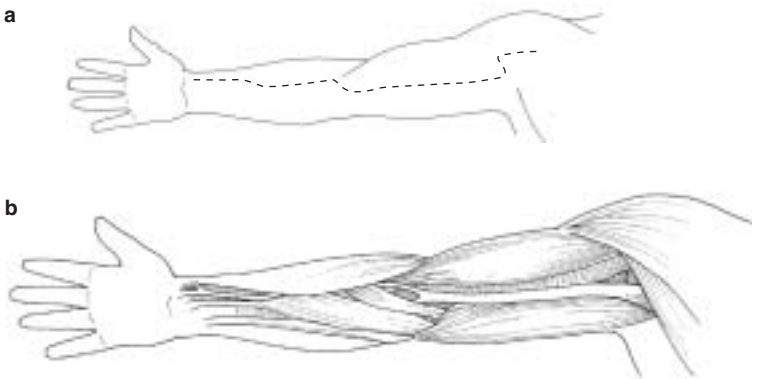


Fig. 27-5. Exposure of brachial and radial arteries.

- o Longitudinal incisions usually directly over injured vessel followed by **proximal and distal control**. A tourniquet (eg, blood pressure cuff) may occasionally be useful to obtain proximal control or to improve intraoperative visualization.
- o **Once control is obtained, perform the following steps:**
 - ◆ Debride injured vessels to macroscopically normal wall.
 - ◆ Pass balloon catheters proximal and distal to remove any residual thrombus.
 - ◆ Flush both directions with heparinized saline.
- o Consider temporary intraluminal shunting.
 - ◆ Successful shunt placement allows ample time for wound debridement and copious irrigation, identification of nerve injuries, and careful consideration of reconstruction vs primary amputation.
- **Shunt placement technique.**
 - o Proximal and distal vessel control with Silastic vessel loops or Rumel tourniquet.
 - o Release proximal control to flush clot and place Argyle shunt.
 - o Distal thrombectomy (Fogarty catheter) until no clot is returned.
 - o Instill heparinized saline (20 U/mL) into distal vessel.
 - o Place shunt into distal end and secure.
 - o Check for distal pulse/perfusion.
- In injuries to **both artery and vein** in which no shunt is used, **repair artery first** to minimize ischemic time, followed by venous repair.
- **Suture:** 5-0 or 6-0 Prolene; 7-0 Prolene for small arteries. All completed repairs must be tension free.
- Upon completion, forward and back bleed repaired segment until clear of air and debris prior to final closure.
- **Type of repair** will depend on the extent of injury.
 - o **Lateral suture repair:** Required for minimal injuries that, when repaired, will not compromise the lumen > 25%, result in a thrill, nor decrease pulse or Doppler signal.
 - o **Patch angioplasty:** Needed for larger, tangential wounds; to prevent stenosis.
 - o **End-to-end anastomosis:** Excise extensively damaged segments and perform anastomosis if able to mobilize ends (generally, < 2 cm gap) without tension. An oblique anastomosis is less likely to stenose.

- o **Interposition graft:** Required if the vessel cannot be primarily repaired without undue tension.
 - ◆ **Autogenous vein** grafts preferred, usually the contralateral greater saphenous vein (GSV).
 - ◇ Harvest vein from the contralateral limb, if possible. The reason for this is in the injured limb, superficial veins may be an important source of venous outflow if deep veins are injured.
 - ◇ Order of preference vein harvest for arterial conduit is contralateral GSV, ipsilateral GSV (if no concomitant deep venous injury), contralateral lesser saphenous vein (LSV), ipsilateral LSV (if no deep venous injury), cephalic vein, and basilic vein.
 - ◆ **Prosthetic** grafts may be required when autogenous vein is inadequate or unavailable, expeditious repair is indicated, or for large vessels (aortoiliac system) for which there is a large size discrepancy.
 - ◇ Polytetrafluoroethylene (PTFE) grafts are more resistant to infection than Dacron and have acceptable patency rates when used in the above-knee position.
 - ◇ **The use of prosthetic grafts can hasten the completion of a procedure in patients whose physiology requires expeditious surgery.**
 - ◇ **Prosthetics can also be used in areas of extensive soft-tissue debridement as a “prolonged shunt” where planned revision days to weeks later, out of theatre, will be expected.**
- **Graft coverage:** Exposed vein grafts will desiccate, leading to graft blow-out and potential exsanguination. They must be covered by soft tissue or muscle; superficial muscles such as sartorius or gracilis in the thigh may be mobilized to cover a graft. If coverage is not possible, an alternate subcutaneous or subfascial route through uncontaminated viable tissue must be chosen.
- **Prolonged shunting:** If the above techniques are unsuccessful or precluded by patient physiology or the tactical environment, shunting (as outlined above) with the following modifications can be used for up to 72 hours.
 - o Replace silastic loops with suture, and **secure firmly.**

- o Systemic heparinization is not required.
- o Monitor distal perfusion hourly.
- o Re-evaluate/evacuate early for definitive repair.
- **Ligation of artery:** If the above options for repair are unsuccessful or unavailable, vessels can be ligated in light of known rates of morbidity. **Emphasis is Save Life Over Limb.**
- **Intraoperative completion angiogram** or duplex US (if available) should be done to evaluate the technical adequacy of the repair, visualize the runoff, and detect any missed distal clot.
 - o Full strength contrast 30–60 cc.
 - o 20 gauge Angiocath.
 - o Inflow occlusion.
- **Venous repair:** Options are similar to arterial repairs outlined above.
 - o **Ligation** of major veins is acceptable in life-threatening situations, although in a stable patient and time permitting, venous repair should be performed and may enhance arterial repair patency.
- **Compartment syndrome:** Muscle compartments of the forearm and palm in the upper extremity and anterior compartments of the lower leg are particularly susceptible.
 - o Indications for fasciotomy:
 - ◆ 4–6 hour delay after vessel injury.
 - ◆ Combined vein and artery injury.
 - ◆ Arterial ligation.
 - ◆ Concomitant fracture/crush, severe soft-tissue injury, muscle edema or patchy necrosis.
 - ◆ Tense compartment/compartment pressures exceeding 40 mm Hg.
 - ◆ Prophylactic for patients with prolonged transport times or long periods without observation (no surgical care available enroute).
 - o A standard two-incision, four-compartment approach for the calf is simple and effective (see Chapter 22, Soft-Tissue Injury).
 - o Arm fasciotomy will consist of a longitudinal centrally placed incision over the extensor compartment and a curvilinear incision on the flexor aspect beginning at the antecubital fossa.

- **Post-op care.**
 - Palpable pulses obtained in the operating room (OR) should remain palpable post-op.
 - ◆ Pulse changes, even if Doppler signals remain, may indicate graft thrombosis and should be investigated.
 - Consider low-dose heparin as deep vein thrombosis (DVT) prophylaxis.
 - ◆ Use with caution in multiply injured and head-injured patients.
 - Slight elevation of injured extremity improves post-op edema.

