

Injuries to the Hands and Feet

Introduction

Combat injuries to the hands and feet differ from those of the arms and legs in terms of mortality and morbidity. Death is rare, but a minor wound, causing no lasting impairment if inflicted, for example, on the thigh, can result in life-long disability when it occurs in a hand or foot. The hands and feet have an important commonality: an intricate combination of many small structures that must function smoothly together.

Types of Injury

- Nonbattle injuries resulting in laceration of the hands and crush injuries involving either the hands or feet are common. Such crush injuries may result in compartment syndrome.
- Missile and blast injuries involving the hands and feet are common in combat and may result in mutilating injuries with a permanent loss of function.

The Hand

Even apparently minor wounds distal to the wrist crease may violate tendon sheaths and joints, resulting in a serious deep space infection. Such wounds require a high index of suspicion for injury and a low threshold for operative exploration.

Evaluation and Initial Management

- The casualty's upper extremities should be exposed.
- Rings, watches, and other constrictive material must be removed immediately.

- A preliminary neurologic exam should be performed and documented.
- Vascular status of the hand should include an assessment of radial and ulnar arteries (Allen test, Doppler, among others).

Treatment of Hand Compartment Syndrome

- The hand has 10 separate fascial compartments (4 dorsal interossei, 3 volar interossei, the thenar muscles, the hypothenar muscles, and the adductor pollicis [Fig. 26-1]).

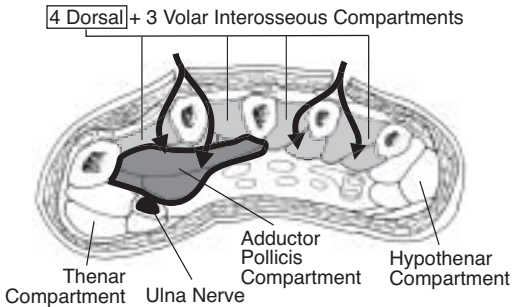


Fig. 26-1. Compartments of the hand.

- A complete hand fasciotomy consists of four incisions (shown in Fig. 26-2).
- One incision on the radial side of the thumb metacarpal releases the thenar compartment.
- A dorsal incision over the index finger metacarpal is used to release the 1st and 2nd dorsal interossei, and to reach ulnar-to-index finger metacarpal and to release the volar interossei and adductor pollicis.

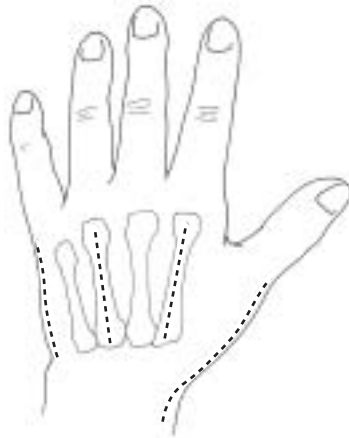


Fig. 26-2. Hand fasciotomy incisions.

- A dorsal incision over the ring finger metacarpal is used to release the 3rd and 4th dorsal interossei, and to reach down along the radial aspect of the ring finger and small finger metatarsal to release the volar interossei.
- An incision is placed at the ulnar aspect of the small finger to release the hypothenar muscles.
- Although compartments are not well defined in the fingers, grossly edematous fingers may require release of dermal and fascial constriction; care should be taken to place the skin incision away from the neurovascular bundles (Fig. 26-3).

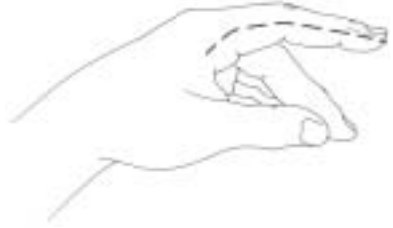

Fig. 26-3. Incisions for finger fasciotomy.

Surgical Technique

Do not blindly clamp bleeding tissues because nearby nerves may be injured. If unable to control the bleeding with pressure, isolate the vessel under tourniquet control and tie off or clamp under direct vision.

- General or regional (block) anesthetic is required; local infiltration of anesthetic is inadequate. Epinephrine is never injected into the hands or fingers.
- Although either the radial or ulnar artery may be ligated, both should not be.
- Thorough exploration under tourniquet down to normal tissue is mandatory to define the extent of the injury.
- Debridement removes buried foreign matter and deep devitalized tissue.
 - Dead tissue is removed.
 - Tissue, including skin, with marginal or questionable viability is left for subsequent evaluation to improve chances for optimal outcome.
- The fingers are not amputated unless irretrievably mangled.

- Viable tissue, even though nonfunctional, is retained and stabilized for later reconstruction.
- Provisional stabilization of fractures with Kirschner wires (K-wires) may enhance patient comfort and later management.

Specific Tissue Management

- **Bone:** Unless extruding from the body or severely contaminated, fragments should be left in place. At forward hospitals, only small K-wires should be used for internal fixation.
- **Tendon:** Minimal excision of tendons should occur. No attempt at repair should be made in the field.
- **Nerve:** Do not excise nerve tissue. No attempt at repair should be made in the field.
- The ends of lacerated nerves and tendons may be tagged with 4-0 suture so that they may be more easily identified later during definitive reconstruction and repair.

Closure of wounds is delayed; however, exposed tendon, bone, and joint should be covered with viable skin, if possible, to prevent desiccation.

Dressing and Splinting

Splint the hand in the safe position (Fig. 26-4). The wrist is extended 20°, the metacarpalphangeal joints are flexed 70°–90° and the fingers (proximal and distal interphangeal joints) are in full extension.

- Fine mesh gauze is first laid on the wounds and covered with a generous layer of fluffed gauze.
- The entire wound should be covered but the fingertips left exposed, if possible, to evaluate perfusion.

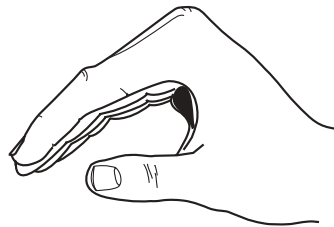


Fig. 26-4. Hand splint position.

- A splint is applied, immobilizing all injured parts and extending one bone or joint beyond. A palmar plaster slab is routine, but a dorsal one may be added for additional stability.

The Foot

Penetrating injuries of the foot frequently result in prolonged morbidity and disability. Crush injuries and injuries from blast are more likely to result in an unsatisfactory result than are wounds made by low-velocity bullets or isolated fragments. This is especially true when there is loss of the heel-pad, significant neurovascular injury or when the deep plantar space has been contaminated. The ultimate goal of treatment of these injuries is a relatively pain free, plantigrade foot with intact plantar sensation.

Evaluation and Initial Management

- The zone of injury with both open and closed injuries of the foot is often more extensive than is apparent with the initial inspection.
- The vascular status of the foot should be assessed by palpation of the dorsalis pedis and posterior tibial pulses. An assessment of capillary refill in the toes should also be made as a compartment syndrome of the foot can coexist with intact pulses.
- Anesthesia of the plantar aspect of the foot indicates an injury to the posterior tibial nerve or one of its major branches and portends a poor prognosis for a satisfactory outcome.
- Compartment syndrome of the foot can occur even in the presence of an open foot injury, and when identified, requires emergency treatment.
- At the time of debridement, small, contaminated bone fragments without soft tissue attachment should be removed.
- High-volume irrigation for all open wounds is mandatory.

All wounds should be left open.

Injuries to the Hindfoot

- Severely comminuted, open fractures of the talus may require talectomy, but this decision should be left to higher levels of care.
- The talus is best debrided through an anterolateral approach to the ankle extended to the base of the 4th metatarsal.
- Penetrating wounds into the plantar aspect of the heel pad can be approached through a heel-splitting incision to avoid excessive undermining of this specialized skin.
- Transverse gunshot wounds of the hindfoot are best managed by medial and lateral incisions with the majority of surgery performed laterally to avoid medial neurovascular structure.

Injuries to the Midfoot

- Tarsal and metatarsals are best approached through dorsal longitudinal incisions. In addition, compartment release can be adequately performed through longitudinal incisions medial to the 2nd metatarsal and lateral to the 4th metatarsal in order to leave a wide skin bridge.
- Contamination of the deep plantar compartments of the foot is best managed through a plantar medial incision that begins 1 inch proximal and 1 inch posterior to the medial malleolus and extends across the medial arch ending on the plantar surface between the 2nd and 3rd metatarsal heads. The medial neurovascular structures must be identified during this approach. A full compartment release can also be performed through this incision.

Injuries to the Toes

- Every effort should be made to preserve the great toe.
- Amputation of the lateral toes is generally well-tolerated.

Foot Compartment Syndrome

- There are 5 compartments in the foot.
 - The interosseous compartment is bounded by the lateral 1st metatarsal medially, metatarsals and dorsal interosseous fascia dorsally, and the plantar interosseous fascia plantarly.

- o The lateral compartment is bounded by the 5th metatarsal shaft dorsally, the plantar aponeurosis laterally, and the intermuscular septum medially.
- o The central compartment is bounded by the intramuscular septum laterally and medially, the interosseous fascia dorsally, and the plantar aponeurosis plantarly.
- o The medial compartment is bounded by the inferior surface of the 1st metatarsal dorsally, the plantar aponeurosis extension medially, and the intramuscular septum laterally.
- o The calcaneal compartment contains the quadratus plantae muscle.
- The foot may be released through a double dorsal incision.
- One incision placed slightly medial to the 2nd metatarsal, reaching between the 1st and 2nd metatarsals into the medial compartment, and between the 2nd and 3rd metatarsals, into the central compartment (Fig. 26-5).
- A second dorsal incision is made just lateral to 4th metatarsal, reaching between 4th and 5th metatarsals into the lateral compartment.
- To spare the dorsal soft tissue, a single incision medial fasciotomy may be used.

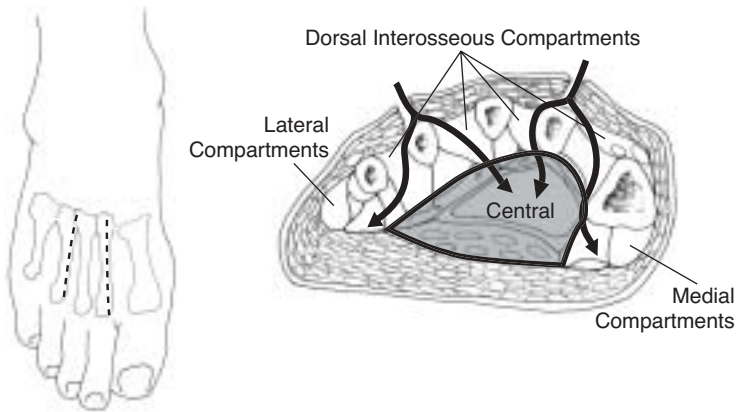


Fig. 26-5. Interosseous compartment releases through two dorsal incisions.

- A medial approach to the foot is made through the medial compartment, reaching across the central compartment into the interosseous compartment dorsally and lateral compartment releasing all the way across the foot (see description in this chapter's Injuries to the Midfoot and Fig. 26-6).
- Fasciotomy wound management.
 - Following the fasciotomy, the fasciotomy wound undergoes primary surgical wound management; all devitalized tissue is removed.
 - As with all battle wounds, the fasciotomy is left open and is covered with a sterile dressing.

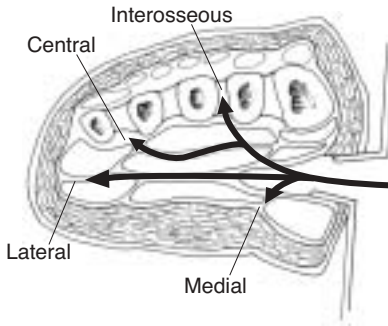


Fig. 26-6. Central compartment releases through medial approach.

Stabilization

- K-wires can be utilized for temporary stabilization.
- A bivalved cast or splint is adequate for transport to a site of more definitive care.