

Open-Joint Injuries

Introduction

Open injuries to the joints are rarely immediately life threatening. They are frequently quite dramatic in appearance and draw the inexperienced caregiver's attention away from the truly life threatening, associated injuries. **Neurovascular structures are in close proximity to the major joints, and may require vascular management and repair.** Open joints have long-term morbidity and some secondary mortality from infection due to missed injury or inadequate treatment.

All open-joint injuries must be explored and treated within 6 hours to prevent infection and joint destruction.

With rare exceptions, **closed**-joint injuries should be treated nonoperatively in the combat zone. Definitive intervention and rehabilitation usually require months before complete recovery. Thus, patients with closed injuries to major joints should be evacuated from the theater for definitive surgical intervention and rehabilitation.

The key to treating open-joint injuries is recognition. Once identified, goals are prevention of infection and preservation/restoration of normal joint function.

- Signs of possible open-joint injury are a wound associated with the following:
 - Proximity to a joint.
 - Periarticular fracture.
 - Exposed joint.
 - Effusion.

- o Loss of joint motion.
- o Intra-articular air or foreign body on biplanar radiographs.
- o Abnormal joint aspiration demonstrating hemarthrosis.
- o Extravasation from joint on diagnostic injection.

Open-joint injuries always require surgery. Joint aspiration/injection may be performed to confirm a suspected open joint. If in doubt, treat as an open-joint injury to prevent missed injury sequelae.

- The technique for aspiration / injection involves:
 - o Sterile prep.
 - o 18-gauge needle, 30-cc syringe.
 - o Enter suspected joint, avoiding neurovascular structures.
 - o Attempt aspiration — if blood is aspirated a hemarthrosis is present.
 - o If no hemarthrosis, inject with normal saline (methylene blue if available) until joint is fully distended — the joint is damaged if extravasation is detected.
 - o If there is no extravasation, open joint injury may still be present.
- Approaches for aspiration are shown for the shoulder, elbow (Lateral), knee (Medial parapatellar), and ankle (Antero-lateral) (Fig. 24-1a,b,c,d).

Treatment of All Open-Joint Injury

- IV antibiotics should be started ASAP after wounding, and continued postop for 48 hours.
- Tourniquet control of operative bleeding is essential.
- Standard arthrotomy incisions are utilized (Fig. 24-2a,b,c). (Wound margins are incorporated if possible, provided they do not compromise exposure or create non-viable flaps).
- The extremity must be draped free to allow full range of motion during surgery.
- All intra-articular foreign material, loose cartilage (including flaps), blood clots, and detached bony fragments without major articular surface must be removed.

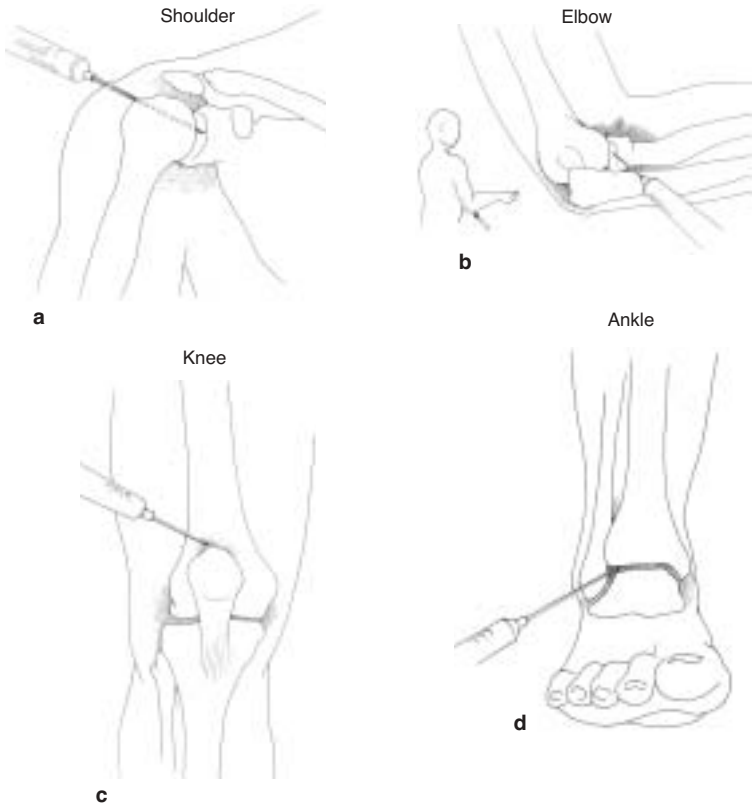


Fig. 24-1a,b,c,d. Aspiration/injection approaches to the shoulder, elbow, knee, and ankle.

- All recesses must be explored and all damaged tissue must be removed.
- The joint must be thoroughly irrigated with normal saline (pulse lavage and 6 to 9 L is recommended).
- Internal fixation is **contraindicated** with the **exception of large articular fragments** that may be stabilized with Kirschner wire (K-wire) or Steinmann pins.

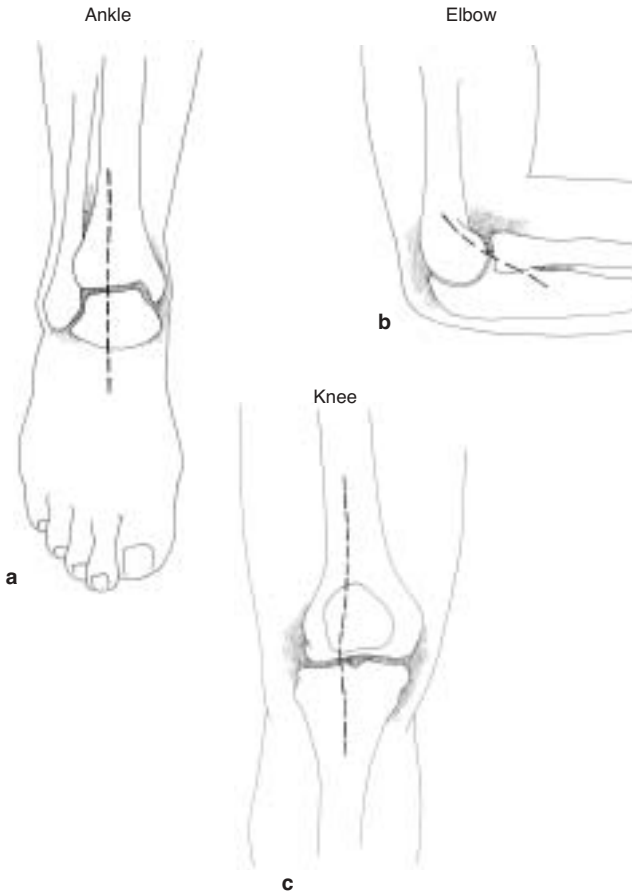


Fig. 24-2a,b,c. Surgical approaches to the ankle, elbow, and knee.

- Close synovium if possible without tension and without surgical tissue advancement. **The remainder of the wound should never be closed at the initial surgical exploration.**
- If synovial closure is not possible, the joint should be dressed open with moist fine mesh gauze occlusive dressing.
- The wound should be reexplored in 48–72 hours.
- A bivalved cast or splints can be used to stabilize the joint.

- If there are delays in evacuation or inability to move the patient, the following steps can be taken:
 - Delayed primary closure (DPC) can be undertaken in 4–7 days if there are no signs of infection.
 - If there is extensive soft-tissue loss, split-thickness skin grafts may be applied to granulating synovium.
- After DPC, gentle range-of-motion therapy is begun, based on consideration of any associated fractures or neurovascular injuries.

Any time joint infection is suspected, the joint should be immediately explored/re-explored.

Signs of Joint Sepsis

- Persistent swelling.
- Marked pain.
- Local warmth.
- Fever.
- **Intense pain with restriction of the range of motion.**

Special Considerations for Hip Wounds

- Open injuries of the hip joint are problematic for several reasons.
 - Difficulty in diagnosis.
 - Highly virulent organisms leading to mortality or long-term morbidity.
- Violations of the hollow viscus organs associated with fractures that extend into the acetabulum or femoral neck uniformly contaminate the joint.
 - Ruling out joint involvement is difficult in the field environment due to poor radiographic support and difficulty in reliable joint aspiration/injection. Therefore, a high index of suspicion with a low threshold for joint exploration is essential for preventing devastating complications.
- Presacral drainage is highly encouraged in rectal injury with joint extension.

Hip Exploration Technique

- Semilateral or lateral decubitus position, with the abdomen, pelvis, and full lower extremity prepped and draped free.
- A tibial traction pin to suspend the leg from the ceiling is advantageous.
- Anterior iliofemoral (Fig. 24-3a,b,c) approach gives the most extensive exposure to the hip, acetabulum, and ilium. (If the incision was extended superior and posterior, closure of the

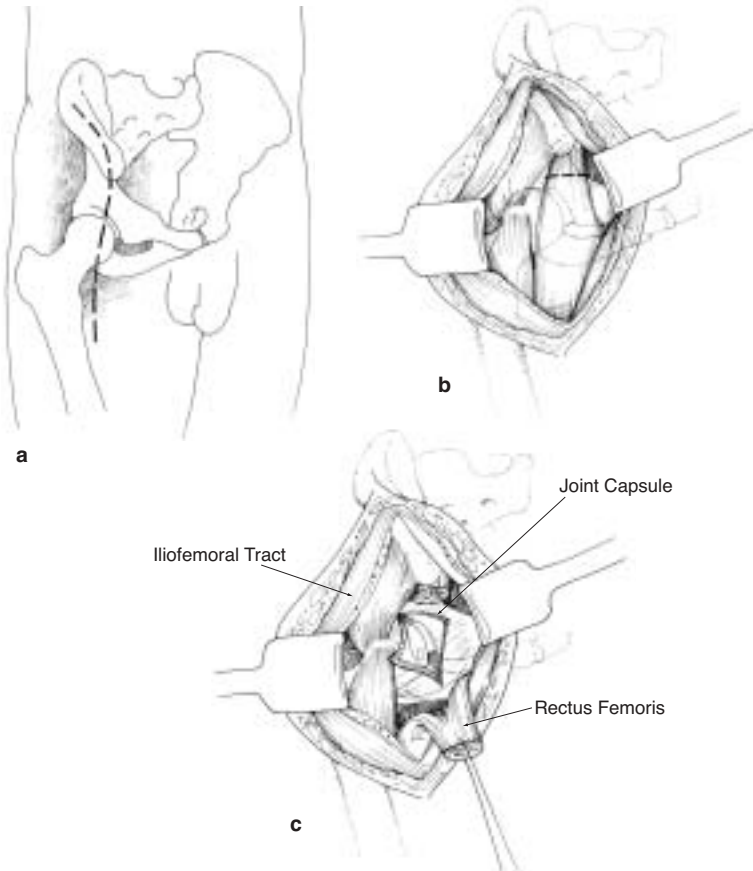


Fig. 24-3a,b,c. Anterior iliofemoral approach to the hip.

superior/posterior aspect of the incision only over the iliac crest is necessary at the initial surgery to prevent muscle retraction and subsequent inability to close the wound.)

- A posterior or Kocher approach (Fig. 24-4a,b) allows for posterior exposure and allows for posterior drainage. It may be used in conjunction with the iliofemoral approach or in select cases alone for debridement. In an echeloned care/delayed evacuation scenario, dependent posterior drainage may be more critical than currently practiced in the civilian environment.

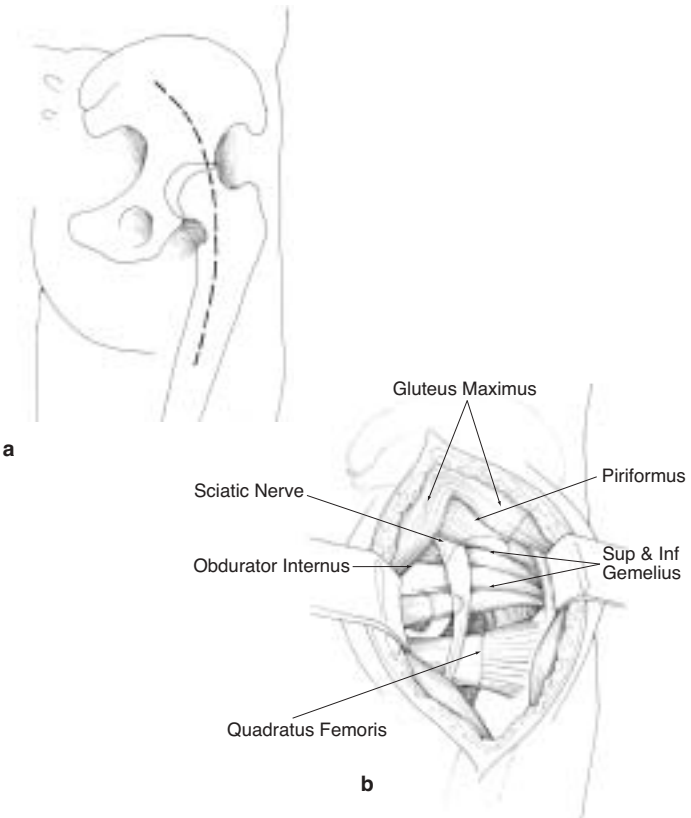


Fig. 24-4a,b. Posterior approach to the hip.

- Complete fractures of the femoral neck/head should be resected due to nearly uniform complications of sepsis and avascular necrosis.
- Except as described above, the surgical incision is not closed. Dressing of the wound is as previously described. The patient may be placed in a spanning external fixator from the iliac crest to the distal femur, or placed in a one and one-half hip spica cast. (See Chapter 23, Extremity Fractures, for diagram.)

Special Considerations for the Shoulder

- Often associated with life-threatening thoracic or vascular injuries. See Chapter 27, Vascular Injuries, for approaches to the axillary and subclavian arteries.
- Technique for shoulder exploration:
 - Semilateral position will allow both anterior and posterior approaches to the glenohumeral joint.
 - Anterior deltopectoral approach is recommended (Fig. 24-5a,b,c,d). (Detachment of the short biceps, coracobrachialis, and pectoralis minor off the coracoid may be needed for adequate exposure.) The subscapularis is detached and the joint capsule is trimmed of devitalized tissue. All attempts are made to preserve the supraspinatus attachment.
 - Loose fragments or a completely devitalized humeral head are resected to prevent infection. In an echeloned care/delayed evacuation scenario, dependent posterior shoulder drainage may be more critical than currently practiced in the civilian environment.
 - At the time of the DPC, 4–7 days later, the infraspinatus and teres minor are reattached if previously detached.
 - A Velpeau dressing is utilized for the wounds.
 - For transport, the shoulder can be wrapped in plaster, suspending the cast from the opposite shoulder for comfort. If this is not feasible, a sling and swath, immobilizing the arm against the chest wall, may be used. These patients will require litter transport.

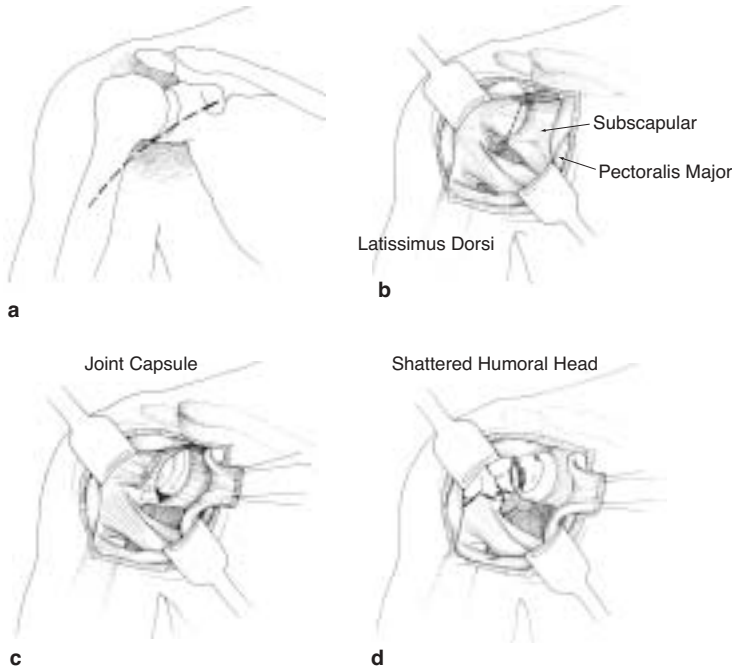


Fig. 24-5a,b,c,d. Anterior deltopectoral approach to the shoulder.

The key to success in dealing with open joints is a high index of suspicion. If the joint is open, then aggressive surgical management is imperative.

