

Extremity Fractures

Introduction

This chapter discusses two techniques for safe transportation of a wounded soldier with a long bone fracture: **transportation casts** and **temporary external fixation**. Both of these methods are acceptable for initial treatment of a patient who will be evacuated out of theater. Precise indications for external fixator use versus casting have not been established.

In general, good indications for external fixator use include when the soft tissues need to be evaluated while en route, such as with a vascular injury; when other injuries make use of casting impractical, such as with a femur fracture and abdominal injury; or when the patients have extensive burns. **Advantages of external fixation** are that it allows for soft tissue access, can be used for polytrauma patients, and has a minimal physiologic impact on the patient. **Disadvantages** are the potential for pin site sepsis or colonization and less soft tissue support than casts.

Advantages of transportation casts are that they preserve the maximum number of options for the receiving surgeon; the soft tissues are well supported, and the casts are relatively low tech. **Disadvantages** are that casts cover soft tissues, may not be suitable for polytrauma patients, and are more labor-intensive than external fixators.

Both transportation casts and external fixators are equally acceptable methods for the initial management of long bone fractures. In the end, the choice of initial fracture stabilization must be made on a case-by-case basis by the treating surgeon. That decision should be based on the surgeon's experience, his/her assessment of the evacuation process, the materials available,

the nature of the patient's wounds and the patient's overall condition.

Though standard in civilian trauma centers, intramedullary nailing of major long bone fractures is **contraindicated** in combat zone hospitals because of a variety of logistical and physiologic constraints. This method may be used once a patient reaches an echelon above corps (EAC) or other site where more definitive care can be provided.

In this chapter, the term **casting material** is used in place of describing either plaster or fiberglass for constructing casts. Both are acceptable materials for application of transportation casts.

General Considerations of Wound Management

- Initial management.
 - Treat by irrigation and debridement as soon as feasible to prevent infection.
 - Femur fractures are at high risk for infection (about 40%, historically).
 - Biplanar radiographs should be obtained.
 - Neurovascular status of the extremity should be documented and checked repeatedly.
 - Internal fixation is contraindicated.
 - Begin IV antibiotics as soon as possible and maintain throughout the evacuation chain. Use a broad spectrum cephalosporin (cefazolin 1 g q 8 h). An aminoglycoside may be harmful for someone in shock or dehydrated. The two most harmful bacteria—clostridia and strep—are covered by a 1st generation cephalosporin.
- Wound incision/excision.
 - Guidelines as per soft tissue injury section.
 - Longitudinal incisions to obtain exposure.
 - Fascia incised longitudinally to expose underlying structures and **compartment release**.
 - All foreign material in the operative field must be removed (Fig. 23-1a, b, c).

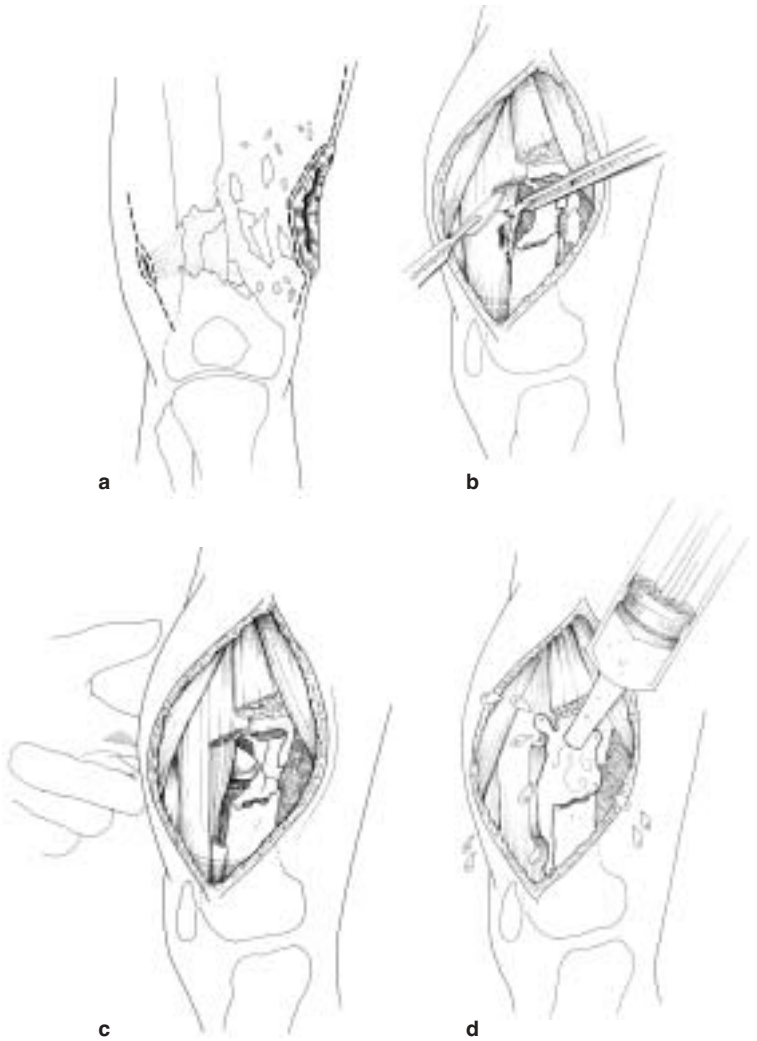


Fig. 23-1. Wound incision/excision.

- o Bone fragments should be retained if they have a soft tissue attachment.

- o Detached bone fragments smaller than a thumbnail are discarded.
- o Larger fragments that contribute to the structural integrity of the long bone should be retained.
- o Irrigation is essential (Fig. 23-1d).
- Closure of wounds.
 - o Primary closure is never indicated. Loose approximation of tissues with one or two retention sutures is appropriate to cover nerves, vessels, and tendons, but there must be a provision for substantial free drainage.
 - o Skin grafts, local flaps, and relaxing incisions are contraindicated in the initial management.
 - o Delayed primary closure may be attempted as described in the section on soft tissue wounds. This should be accomplished in a stable environment.

Transportation Casts

- Introduction.
 - o A transportation cast is a well-padded cast that is unique to the treatment of combat casualties. It is used to transport patients between hospitals and not intended as a means of definitive care.
 - o Definitive reduction is not required with the initial surgical procedure.
 - o The goal of transportation casts is to immobilize a fracture along the evacuation chain. The cast must meet the dimensions of the standard NATO litter (FM 8-10-6).
 - o Transportation casts are applied prior to evacuation.
 - o All casts must be bivalved prior to evacuation. (Hip spica — univalved.)
 - o If a patient is expected to have multiple procedures at the same hospital, balanced skeletal traction should be utilized until the last procedure prior to transportation. The traction pin may be incorporated into the transportation cast.
 - o Slab splinting may not be adequate for transportation, particularly for severely unstable fractures. Splinting is appropriate for stable fractures, particularly in the hand, wrist, forearm, foot, ankle and lower leg.

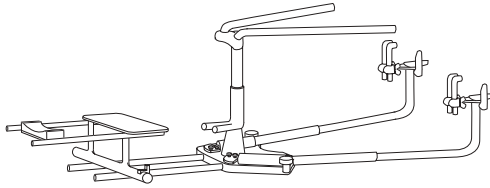


Fig. 23-2. Portable fracture table.

- o Portable skeletal traction should not be used for transportation of a patient.
- o Tobruk splint (a Thomas splint with circular plaster) should not be used.
- **Hip, femur, and knee, and some proximal tibia fractures.**
 - o Low hip spica transportation cast.
 - o Disadvantages: Limited soft tissue access. Not suitable in polytrauma.
 - o Technique.
 - ◆ Adequate anesthesia is given, and patient is placed on fracture table (Fig. 23-2).
 - ◆ Irrigation and debridement as indicated above.
 - ◆ Precise reduction not necessary, but usually requires two assistants.
 - ◆ Stockinette over abdomen, distal thigh of uninvolved side, and foot of the involved side (Fig. 23-3).

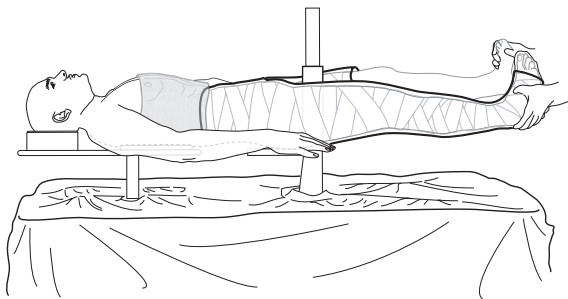


Fig. 23-3. Patient position on fracture table.

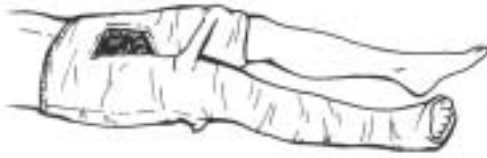

Fig. 23-4. Hip spica transportation cast.

- ◆ Felt padding is placed over sacrum and anterior superior iliac spine (ASIS) and other bony prominences.
- ◆ Towel is placed over abdomen to allow breathing space.
- ◆ Six-inch Webril or similar cotton batting is wrapped, 2-4 layers.
- ◆ Six-inch casting material is then rolled over the Webril from ASIS to the foot on the affected side to the distal thigh on the unaffected side (Fig. 23-4). Splints are applied over the posterior, lateral, or groin areas to reinforce the groin (Fig. 23-5). Use a finishing roll after turning down the edges of the stockinette to give a neat appearance.
- ◆ An adequate perineal space must be left for hygiene.
- ◆ Use a 1/2" dowel or similar material to make anterior/posterior crossbars.
- ◆ Affected knee bent about 20°.
- ◆ Space between feet must not exceed standard litter, although this makes perineal access difficult.
- ◆ Towel is removed, cast is bivalved, and a circular area over the abdomen is cut out.

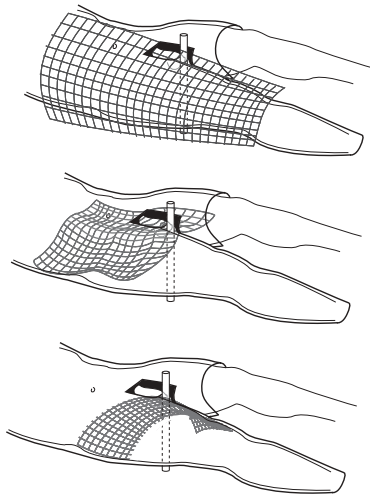


Fig. 23-5. Reinforce cast at hip with splints.

- ◆ Use an indelible marker to draw the fracture configuration, and note the dates of surgery and wounding on the cast.
 - ◆ Support the cast with towels, blankets, or pillows to relieve pressure on the cast, especially the back edge.
- Proximal/**mid/distal tibia and ankle fractures**.
 - Long Leg Cast (Fig. 23-6).

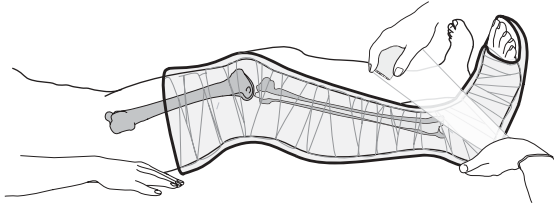


Fig. 23-6. Long leg cast.

- Technique.
 - ◆ The foot, leg, and thigh are placed in a stockinette at the conclusion of the operation for the open wounds.
 - ◆ Two people are needed to maintain the reduction and apply the cast. Hold the knee flexed about 20° .
 - ◆ Webril applied from the toes to the groin.
 - ◆ Six-inch wide casting material is then rolled over this region, with a turn down of the stockinette prior to the final layer, to make a neat edge.
 - ◆ Reinforce the knee to strengthen the cast.
 - ◆ Make a supracondylar mold to provide support (Fig. 23-7).

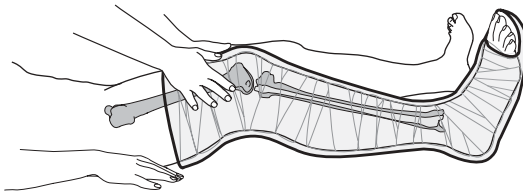


Fig. 23-7. Supracondylar mold of long leg cast.

- ◆ Bivalve the cast.
 - ◆ Label the cast with the dates of injury and surgery, and draw the fracture on outside of the cast.
 - ◆ Elevate the leg so the tibia is parallel to the litter or bed.
- **Shoulder and humeral shaft fractures.**
 - Velpeau technique. (External fixator is an acceptable alternative, however without direct visualization there is a high risk of iatrogenic injury to the radial nerve and vascular structures. Review anatomy carefully.)
 - ◆ At the conclusion of open wound treatment, the extremity is manipulated on the fracture table to obtain the best alignment.
 - ◆ Large cotton pads are placed under the axilla and arm (Fig. 23-8a).
 - ◆ The Webril is wrapped around the torso and affected extremity to the wrist (Fig. 23-8b).
 - ◆ Six-inch wide casting material is then wrapped over the extremity and the torso. The first wrap should start around the trunk, go over the shoulder posteriorly, down the arm anteriorly, around the elbow, and then up the posterior aspect of the arm (Fig. 23-8c).
 - ◆ The trunk and the extremity should be wrapped in plaster to stabilize the cast.
 - ◆ Four layers should be sufficient (Fig. 23-8d).
 - ◆ Bivalve this cast, and wrap with elastic bandages. There are no cast saws available on the aircraft. If a patient in a Velpeau cast developed any respiratory problems, emergency measures could not be taken if the cast couldn't be removed.
- **Elbow/forearm.**
 - Long arm cast.
 - Technique.
 - ◆ After treatment of open wounds, the extremity is wrapped in stockinette from the fingers to the axilla.
 - ◆ Gross alignment of fractures is the goal. Precise reduction is not necessary.
 - ◆ Four-inch wide Webril is wrapped from metacarpal heads to axilla.

- ◆ Four-inch wide casting material is applied from metacarpal heads to axilla.
- ◆ Fold the stockinette before finishing layer for a neat edge.
- ◆ Bivalve cast after drying.
- ◆ Reassess neurovascular status.

Bivalving Casts

When a cast is bivalved, it is completely split longitudinally along opposing sides of the cast. Splitting the cast into anterior and posterior halves is preferred. The purpose of bivalving is to allow room for soft tissue swelling, thus lessening the chance

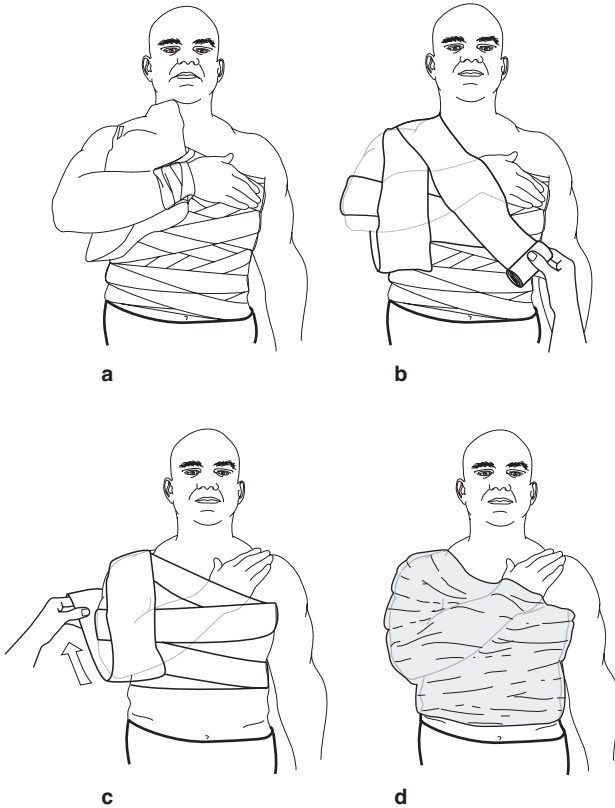


Fig. 23-8a. Padding Velpeau.

Fig. 23-8b–c. Webril application for Velpeau cast.

Fig. 23-8d. Completed Velpeau cast.

of postcasting compartment syndrome. It is important that the underlying cast padding also be completely split underneath the cast cuts; otherwise, the cast padding can restrict swelling and a compartment syndrome could still develop.

External Fixation

- General technique: The surgeon should be familiar with four types of standard constructs of external fixation for use in the initial care of battle casualties: femur, tibia, knee, and ankle. External fixation can also be applied for humerus and ulna fractures as needed.
 - A thorough understanding of the anatomy of the lower extremity is essential for application of the pins in a safe corridor.
 - The external fixator for military purposes should be modular and allow for building up or down as healing progresses.
 - Application of the external fixator may be done without the use of plain films or fluoroscopy.
 - Pins can be inserted by hand using a brace without power instruments.
 - Enough pins should be used to adequately stabilize the fracture for transport. This is usually two per clamp, but three may occasionally be required.
 - The present external fixation system (Hoffmann II) allows for the use of either single pin clamps or multipin clamps. Both clamps are acceptable to use in standard constructs.
 - Multipin clamps provide greater stability and are the current fixators fielded. Dual pin placement (with multipin clamps) is described here. The technique for single pin placement is similar.
- **Femur diaphyseal fracture technique.**
 - The entire limb is prepared for surgery, from the ASIS to the toes.
 - A standard OR table or portable fracture table may be used.
 - An assistant should apply counter pressure while pins are inserted.
 - Precise reduction is not necessary. A padded “bump” under the thigh will help reduce the fracture (Fig. 23-9).

- o The position of the proximal femur should be identified by palpation. A 1-cm longitudinal stab incision is made over the midaxis, or midlateral axis, of the femur (Fig. 23-10). The pin closest to the fracture hematoma, and at least three fingerbreadths from the fracture (Fig. 23-11).
- o Bluntly spread with a clamp down to bone. Put the pin down on the bone, and determine the midportion of the bone by moving the pin back and forth across the width of the femur. You do not want to plunge to one or the other side. Your assistant should provide stability and counter

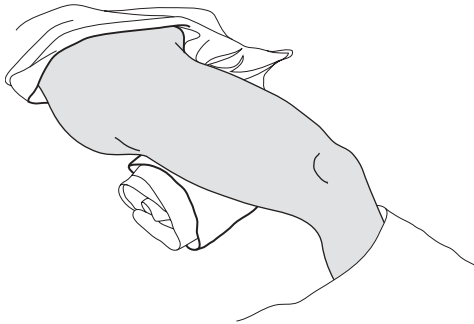


Fig. 23-9. Placing a towel underneath the thigh helps to reproduce the bow of the femur.

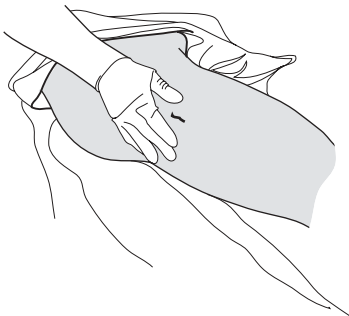


Fig. 23-10. A 1-cm or so incision directly over the middle of the bone, cut in a longitudinal direction.

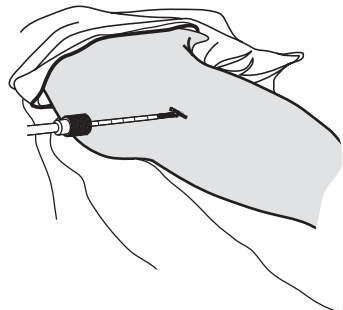


Fig. 23-11. Femur pin placement.

pressure. Two taps on the end of the bit brace should provide an indent in the bone and allow you to start insertion. Apex pins are placed by hand. There is no predrill nor power insertion. 5-mm half-pins should be used. Insert the pin in the midportion of the bone through both the near and far cortex of the bone (Fig. 23-12). The pin will move easier as it enters the intermedullary canal, and then get more difficult to drive as it enters the far cortex.

- o Place a multipin clamp over the inserted pin (Fig. 23-13). Ideally, the pin should occupy one of the end positions (eg, position 1, Fig. 23-14).
- o Using the clamp as a guide, insert a second pin through the clamp. An assistant should hold the clamp. Ensure that the clamp is aligned to the bone and that bicortical purchase is obtained with the second pin. The second pin must be parallel to the first (Fig. 23-15). Use the pin sites that are the farthest apart on the clamp as possible for biomechanical stability (clamp positions 1 and



Fig. 23-12. Bicortical placement of 5-mm half-pin.

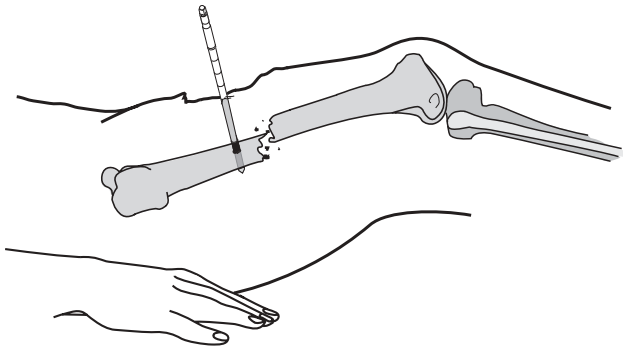


Fig. 23-13.

5 are best, see Fig. 23-14). A third pin may be inserted if needed for additional clamp stability.

- o Apply a second multipin clamp and pins in the same manner to the distal femoral fracture fragment.
- o Connect the two clamps with elbows, bar-to-bar clamps, and two longitudinal bars placed parallel to each other (Fig. 23-16).

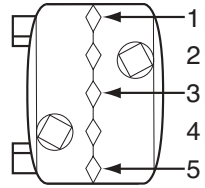


Fig. 23-14. Multipin clamp showing pin positions 1-5.

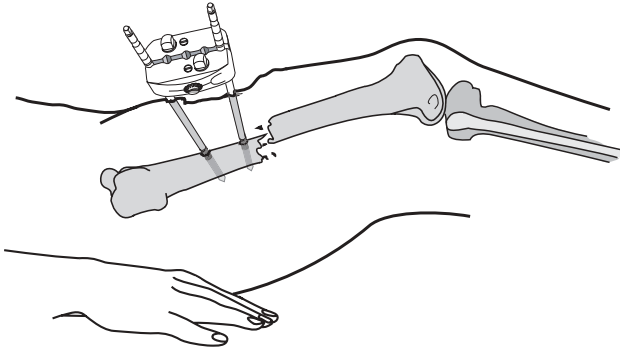


Fig. 23-15.

- o Reduce the fracture with longitudinal traction. Manipulating the fracture fragments using the clamps may be helpful. Once adequate reduction is achieved, tighten all the connections. Precise reduction is not necessary.
- **Tibia shaft fracture technique.**
 - o Palpate the anterior-medial border of the tibia. Place a 1-cm longitudinal incision over the midportion of the surface (Fig. 23-17). The pin closest to the fracture site should be outside the hematoma and at least three fingerbreadths away from the fracture site (Fig. 23-18).

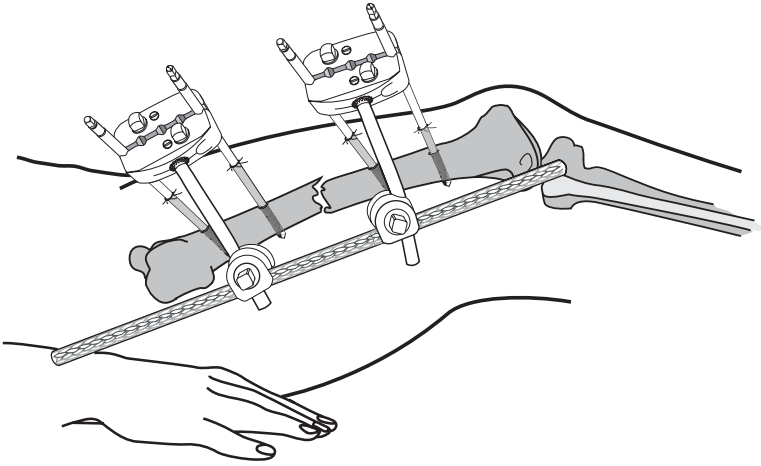


Fig. 23-16.

- o Insert one pin into either the proximal or distal fragment, engaging both cortices. This pin should be placed perpendicular to the subcutaneous border of the tibia, and centered across the width of the tibia (Fig. 23-19).

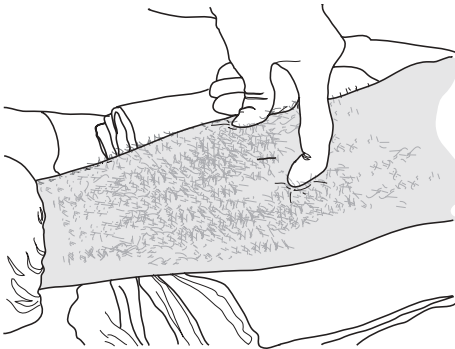


Fig. 23-17. Palpation of the anterior and posterior margins of the medial face of the tibia where a 1 cm incision has been made midway between these two points.

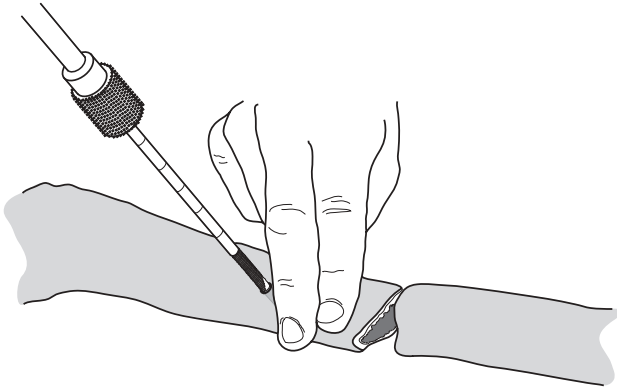


Fig. 23-18. The anteromedial surface is the safest way to introduce pins to the tibia. The pin should be a minimum of two or three fingerbreadths from the fracture site.

- o Using the clamp as a guide, insert a second pin through the clamp. An assistant should hold the clamp. Ensure that the clamp is aligned to the bone and that bicortical purchase is obtained with the second pin. The second pin

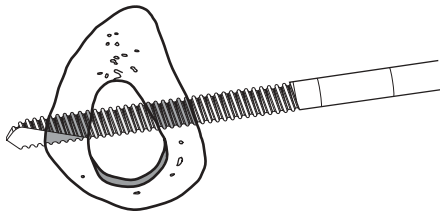


Fig. 23-19. This is the ideal bicortical placement for a pin in the tibia.

must be parallel to the first. Use the pin sites as far apart on the clamp as possible for biomechanical stability (Figure 23-20 and positions 1 and 5 in Fig. 23-14). The second pin should be through the clamp farthest away from the fracture site (Fig. 23-20).

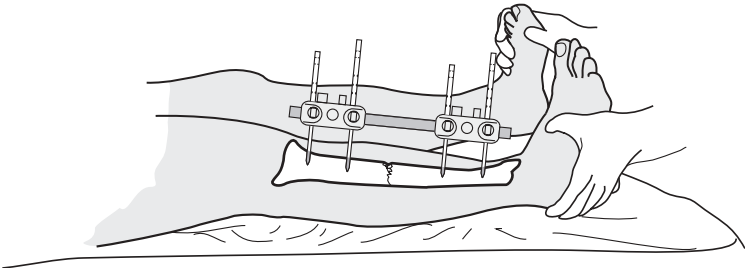


Fig. 23-20. Application of tibia external fixation with multipin clamps.

- o Apply a second multipin clamp and two pins in the same manner to the other main fracture fragment (Fig. 23-21). Connect the two clamps via two elbows, bar-bar clamps, and a single bar (Fig. 23-22).
- o Most battle caused fractures are comminuted; therefore, a second bar should be added to the construct (Fig. 23-23). Use a single bar for stable fractures only.
- o Check the reduction.

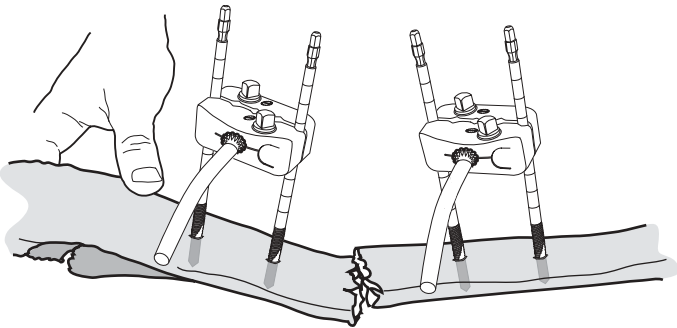


Fig. 23-21. Application of the second multipin clamp and two pins. Repeat those steps with the other major fracture fragment so that you have two sets of multipin clamps as shown here. You will then add the 30 degree elbows as shown here, pointing them in a direction that allows for the best access. At this point you should have gross alignment of the fracture.

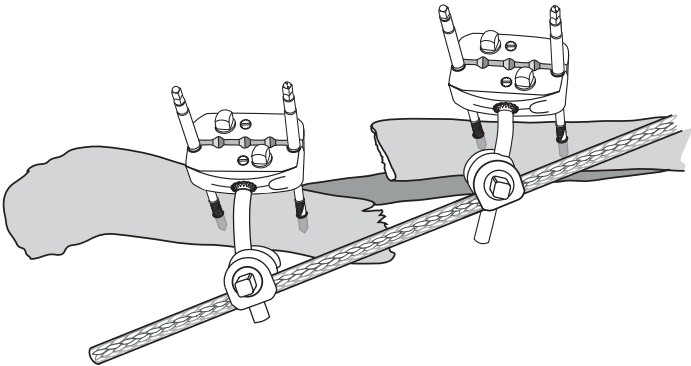


Fig. 23-22. Addition of the cross bar and two bar-to-bar clamps. Have your assistant apply longitudinal traction to reduce the frame, and then tighten the frame in alignment.

- **Technique to span knee.**

- o Indications are proximal tibia fractures, distal femur fractures, or extensive knee injuries, or vascular repairs in the popliteal fossa.

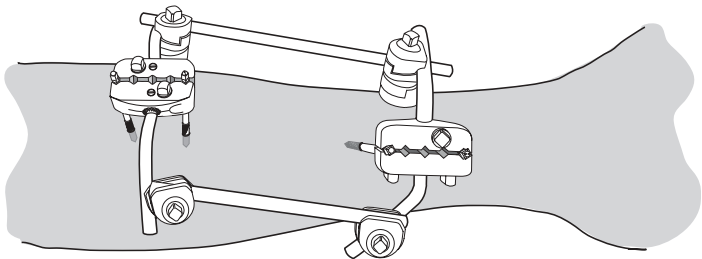


Fig. 23-23. Two-bar apparatus. As the majority of tibia fractures are unstable, it creates a more stable construct by adding a second bar. This requires the use of two of the kits but makes little difference when you are using the tub container at the CSH or equivalent hospitals.

- o Check the distal vascular status of the limb prior to and after the procedure. If there is a vascular injury, refer to Chapter 27, Vascular Injuries.
 - o An assistant will be required to help apply the frame.
 - o General reduction maneuver should be longitudinal traction with slight (10° – 15°) flexion at the knee.
 - o Pins are placed anterior medial on the proximal tibia and antero-lateral on the distal femur. Pin placement should be outside of the zone of injury, at least three fingerbreadths from a fracture site, and outside of the knee joint. At the distal femur, a longitudinal stab incision is made over the antero-lateral aspect of the bone, so that the pin may be inserted into the center of the bone at about a 45° angle from the horizontal. Depending on the fracture configuration, it may also be placed directly anteriorly, though it is generally better to avoid the quadriceps tendon.
 - o Blunt dissection is used to create a corridor to the bone.
 - o A single pin is inserted by hand through both cortices of the bone fragment.
 - o A multipin clamp is used as a guide for a second pin. The second pin **must** be parallel to the first and also bicortical — care should be taken to maintain pin alignment. The proximal tibia should be palpated on the anterior medial surface and the anterior and posterior border should be identified. Midway anterior/posterior, a 1-cm longitudinal stab incision should be made and a blunt soft tissue dissection made to bone.
 - o A multipin clamp should be used as a guide to insert a second pin in the proximal tibia.
 - o The two pin clusters (femur and tibia) should be connected via two elbows, two bar-bar clamps, and a single bar. The knee should be aligned.
 - o A second bar should be added in the manner described above.
- **Technique to span ankle.**
 - o An assistant will be required to help apply the frame and reduce the ankle.

- o General indications are for open distal tibia fractures and open ankle wounds.
- o Pins should be inserted on the anterior medial surface of the tibia and the medial aspect of the calcaneus.
- o Check the distal vascular status prior to and after the procedure. Mark where the posterior tibial and dorsalis pedis artery pulses can be felt.
- o Palpate the anterior medial border of the tibia. Make a 1-cm longitudinal incision midway between the anterior and posterior border of the tibia. Insert the most distal pin on the tibia outside the zone of injury, at least three fingerbreadths from the fracture site.
- o Using a multipin clamp as a guide, insert a second pin in the tibia more proximal to the first. The pin **must** be parallel and be aligned in the longitudinal axis to the first.
- o Palpate the medial border of the calcaneus. Make a longitudinal incision over the calcaneus **away from the posterior neurovascular structures**: dissect to the bone with a clamp and insert the pin.
- o Using a multipin clamp as a guide, insert a second pin in the calcaneus.
- o Connect the two clamps via two elbows, two bar–bar clamps, and a single bar.
- **Skeletal traction.**
 - o Skeletal traction provides a quick means to immobilize a large number of fracture cases with a minimum of technical support.
 - o Indications.
 - ◆ Patients who are expected to have more than one procedure in the same forward hospital prior to evacuation.
 - ◆ Large casualty load.
 - o Technique.
 - ◆ Large threaded Steinman pins are used to obtain skeletal traction of a femur or tibia.
 - ◆ Aseptic preparation of a pin site is necessary prior to placement.
 - ◆ Apply local anesthetic to pin site.

- ◆ Incise skin and dissect to bone bluntly.
- ◆ For femur fractures, incision is made 2 cm posterior and lateral to the tibial tuberosity (directly under, as in Fig. 23-24). Place pin from lateral to medial through and through the proximal tibia.
- ◆ Apply a Thomas splint with Pierson device, with weight applied midhigh (10–20 lb), to the leg (10–20 lb), and to the traction pin (20–40 lb) to obtain balanced skeletal traction as shown in Fig. 23-25.
- ◆ For tibia fractures, incise medially 2 cm anterior and 2 cm cephalad from the tip of the heel. Place the pin from medial to lateral through and through the calcaneus. Place the leg on a Bohler-Braun frame and apply traction to the calcaneal pin (10–20 lb).
- ◆ Wait at least $\frac{1}{2}$ hour after applying traction to obtain radiographs.

● **Care in the evacuation chain.**

- **Patients do not improve in the evacuation system.**

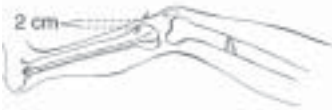

Fig. 23-24. Thomas splint with Pierson device.

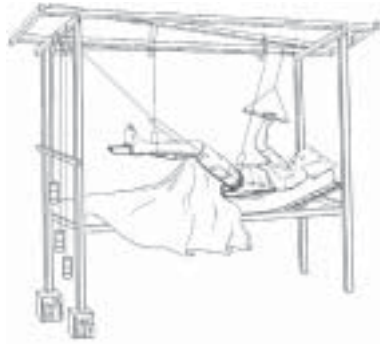

Fig. 23-25. Bohler-Braun frame with traction.

Consider patient safety during evacuation when planning procedures.

- Medications should be arranged prior to departure. **Ensure adequate pain control.**
- Skeletal traction should **not** be used for transportation.

- o Casts should be bivalved. Follow neurovascular status during transport because **casts may act as tourniquets due to tissue swelling.**
- o All documentation, including radiographs, should accompany the patient.