

Abdominal Injuries

Introduction

Changing patterns of warfare together with improvements in protective body armor combine synergistically to minimize truncal trauma incidence, severity, and mortality, despite increasingly lethal weapons systems. Despite these advances, penetrating abdominal trauma still occurs and treatment of these injuries will always be an important component of war surgery.

Trauma to the abdomen, both blunt and penetrating, can lead to occult injury that can be devastating or fatal if not treated. In the unstable patient with abdominal injury, the decision to operate is usually straight forward and should be acted on as soon as it is made. In a few rapidly hemorrhaging patients with thoracoabdominal injuries, a rapid decision must be made as to which cavity to enter first. This chapter addresses some of these issues.

Penetrating injuries below the nipples, above the symphysis pubis, and between the posterior axillary lines must be treated as injuries to the abdomen and mandate exploratory laparotomy.

- Posterior truncal penetrating injuries from the tip of the scapula to the sacrum may also have caused retroperitoneal and intra-abdominal injuries. A low threshold for exploratory laparotomy in these patients is warranted when there are not other diagnostic modalities available.

Diagnosis of Abdominal Injury

- Document a focused history to include time of injury, mechanism of injury, previous treatments employed, and any drugs administered.

- Inspection of the chest and abdomen will be the most reliable part of the physical examination, especially regarding penetrating injuries.
- Determine if the patient requires laparotomy, not the specific diagnosis.

Indications for Laparotomy – Who, When, and Where

First imperative is to determine **who** needs surgery.

- Patients **who** have
 - Penetrating abdominal wounds as described in box above.
 - Other penetrating truncal injuries with potential for peritoneal penetration and clinical signs/symptoms of intraperitoneal injury.
 - Blunt abdominal injuries presenting in shock.
- **When and Where.**
 - When aeromedical evacuation is uncertain and will involve substantial distance, unstable patients with life or limb threatening circumstances should undergo laparotomy at the nearest forward surgical team (FST).
 - Stable patients who can tolerate transport and delay of 6 hours or so, should undergo initial controlled resuscitation, presurgical care (including antibiotics), and be transported to the next level of care for surgery.

When the tactical situation is static, aeromedical evacuation effective, and the distance between FST and combat support hospital (CSH) or higher level hospitals is short, all casualties, including those who are unstable, should bypass the FST and be taken directly to a higher level hospital.

Diagnostic Adjuncts

Minimally invasive adjuncts to diagnosis—computed tomography (CT) scan, diagnostic peritoneal lavage (DPL), and ultrasound (US)—have been used to decrease the number of negative laparotomies in stable, blunt abdominal trauma patients in peace-time settings with good follow-up of patients. Some have been used in lieu of laparotomy to evaluate those with penetrating injuries, when the suspicion is high that no intra-abdominal injury has occurred. This practice has the

potential of missing injuries. These diagnostic screening procedures are primarily used in stable patients with a mechanism of injury suggesting abdominal injury, but without an obvious operative indication. They should be relied on only when good follow up is possible. US and, to a limited extent, DPL have some use in the unstable patient to indicate which cavity should be entered first. US and DPL may also serve as triage tools in the mass casualty situation.

Abdominal Ultrasound

- Advantages: Noninvasive, may repeat frequently, quick, easy, identifies fluid in the abdomen reliably.
- Disadvantages: Operator dependant, may miss small amounts of fluid associated with hollow-viscus injuries.
- Sonography (focused abdominal sonography for trauma [FAST]) has become an extension of the physical examination of the abdomen and should be performed whenever available and when abdominal injury is suspected.
 - 3.5 to 5 MHz curved probe is optimal.
 - The abdomen is examined through four standard sonographic windows.
- A FAST examination assists the surgeon to determine the need for laparotomy in blunt-injured patients but does NOT identify specific injuries.
 - A FAST examination does not identify or stage solid organ or hollow-viscous injury, but reliably identifies free intraperitoneal fluid.
- FAST aids in prioritization of penetrating injury patients for the OR.
- FAST aids in identifying which cavity to open first in patients with thoracoabdominal injuries.
- A FAST examination identifies pericardial fluid, and may assist in the diagnosis of hemopneumothorax.

Ultrasound Views

A typical portable sonography device is shown in Fig. 17-1. The standard locations for “sonographic windows” are shown in Fig. 17-2. Examples of positive and negative sonographic examinations are shown in Figs. 17-3 through 17-6.

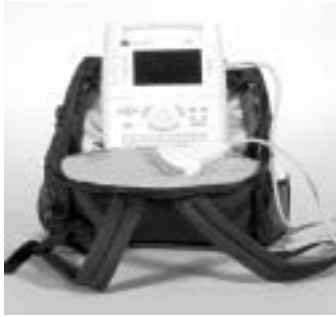

Fig. 17-1. Typical sonography device.

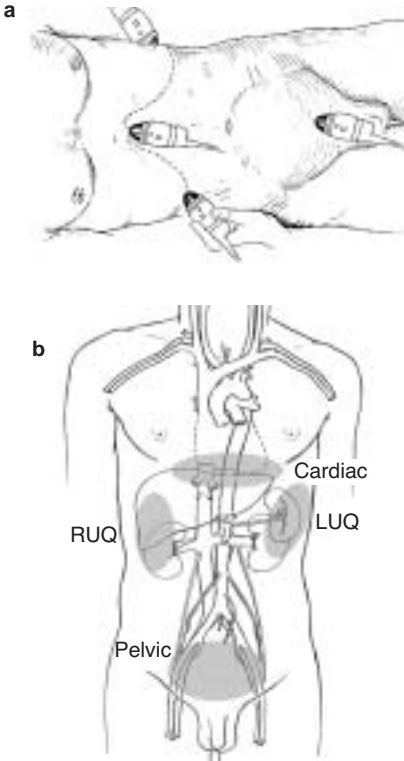
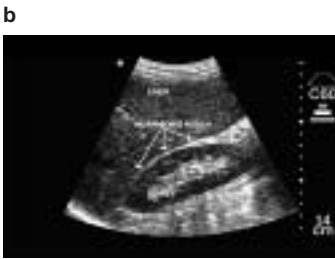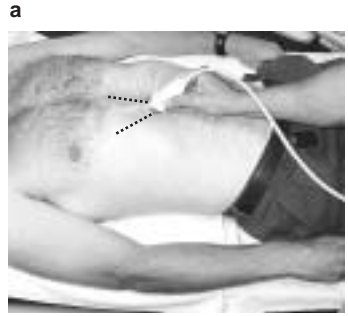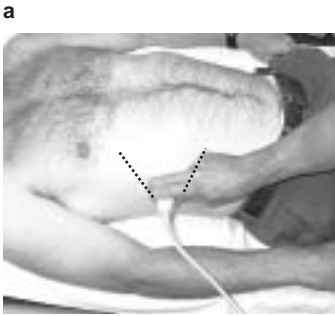


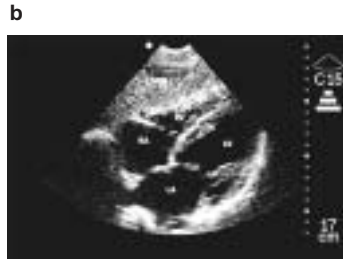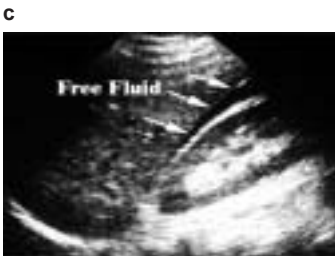Fig. 17-2 a,b. The standard four locations for sonographic windows.



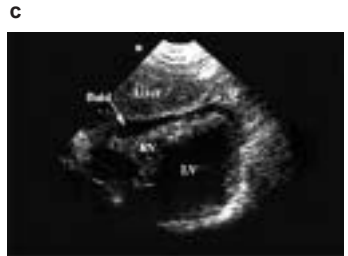normal



normal



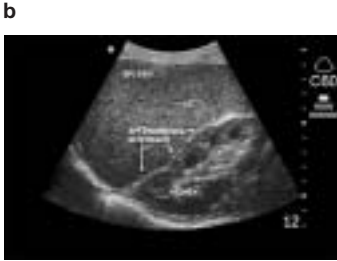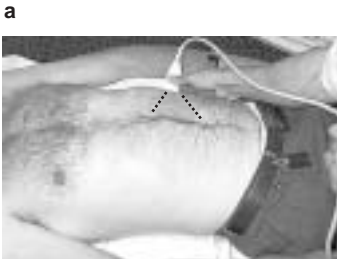
abnormal



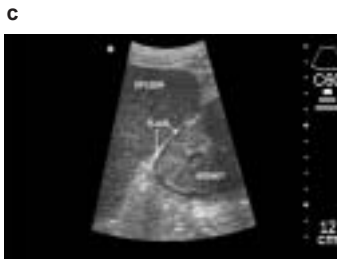abnormal

Fig. 17-3 a,b,c. Normal and abnormal negative sonographic examinations for the right upper quadrant.

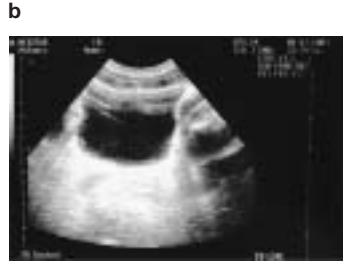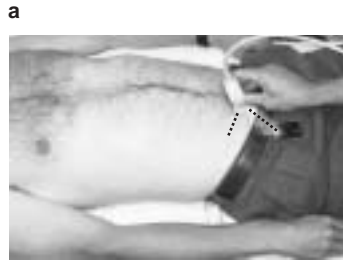Fig. 17-4 a,b,c. Normal and abnormal negative sonographic examinations for the cardiac window.



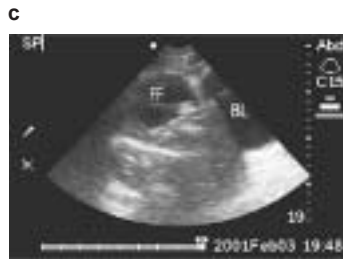normal



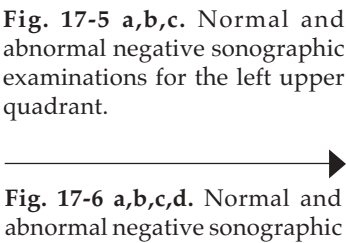
abnormal



normal



abnormal, male



abnormal, female

Fig. 17-5 a,b,c. Normal and abnormal negative sonographic examinations for the left upper quadrant.

—————▶

Fig. 17-6 a,b,c,d. Normal and abnormal negative sonographic examinations for the pelvic window.

Diagnostic Peritoneal Lavage

DPL has been a mainstay of blunt abdominal trauma diagnosis for many years. Unfortunately, in-theatre combat medical units from Level 1 to Level 3 are not routinely outfitted with microscopic laboratory functions to provide cell counts or fluid enzyme determinations. Thus, the only reliable information obtained from DPL is the aspiration of 10 cc of gross blood. Gross blood aspiration is the most infrequently positive criterion of DPL, and its value is probably supplanted by FAST.

- May be useful when US or CT are not available, or as triage tool.
- Requires laboratory for most sensitivity.
 - Blunt: Aspiration of 10 cc of gross blood, RBCs > 1,000,000/mL, WBCs > 500/mL, fecal material.
 - Penetrating: not recommended to ruling out (R/O) injury in penetrating combat wound.
- May help determine which body cavity to enter first in an unstable patient with truncal injury.
- Advantages: Sensitive to small amounts of fluid, including hollow-visceral leaks; fairly quick.
- Disadvantages: Invasive, not repeatable, slower than US.
- Kits allow Seldinger technique.
 - Arrow (AK-09000).
 - Baxter Lazarus-Nelson (MLNK9001).
- Field Expedient substitution: Open technique with small, vertical infraumbilical incision and any tubing (IV, straight or balloon catheter). Cut at least a dozen extra side holes.

CT Scan

- Advantages: Defines injured anatomy in **stable** patients.
- Disadvantages: Slow; requires contrast use and equipment availability; may miss small hollow organ leaks; requires transport away from emergency care area; operator/interpreter dependant; difficult to repeat.

Wound Exploration

- Blast injuries and improvised explosive devices (IEDs) create many low-velocity fragments that may penetrate the skin but not the abdominal cavity. Operative wound exploration in the stable patient with a normal or equivocal examination can help determine the need for formal exploratory laparotomy.
 - When possible wound exploration should be performed in the operating room with adequate instruments and lighting.
 - Finding the fragment in the abdominal wall precludes laparotomy.
 - If the tract is not adequately identified or the fragment seen on plain film cannot be identified, formal laparotomy should be performed.

Operative Planning and Exposure Techniques

- Give broad spectrum antibiotic pre-op, continue for 24 hours.
 - Redose short half-life antibiotics intraoperatively and consider redosing antibiotics with large amounts of blood loss.
- Perform laparotomy through a midline incision.
 - When wide exposure is needed, extend the incision superiorly just lateral to the xiphoid process and inferior to the symphysis pubis.
- Quickly pack all 4 quadrants while looking for obvious injuries.
- Control hemorrhage.
- **Assess physiologic status.**
 - Considering casualty physiology, create operative plan to control contamination and complete operation.
 - ◆ Consider damage control (see Chapter 12, Damage Control Surgery) early and often.
 - ◆ If stabilized/improving, proceed with definitive surgery.
- Identify all organ and hollow-viscus injuries.

- Eviscerate the small bowel to increase workspace.
- Divide the ligamentous attachments of the liver to improve exposure in the right upper quadrant or upper midline.
- Fold the left lateral segment of the liver down and to the right to improve exposure at the gastroesophageal junction.
- Improve exposure to the liver by extending the incision into the inferior sternum and across into the lower right chest (thoracoabdominal).

Stomach Injuries

- The stomach is a vascular organ and will do well after almost any repair.
 - Always enter the lesser sac to determine posterior wall injuries.
- Encircle the distal esophagus with a Penrose drain to provide traction and improve visibility in high midline injuries.
- Minimally debride and primarily close stomach defects.

Duodenum Injuries

Injuries to the Duodenum are associated with massive upper abdominal trauma. Early consideration for damage control surgery should be considered (see Chapter 12, Damage Control Surgery).

- Missed injuries of the duodenum have devastating morbidity.
- Bile staining or hematoma in the periduodenal tissues mandates full exploration of the duodenum (Kocher maneuver).
- Minor injuries can be repaired primarily.
- Major injuries should be repaired if the lumen will not be narrowed by more than 50%. Options for closing injuries of greater than 50%:
 - Close duodenal wall around a tube duodenostomy.
 - ◆ Use a No. 2-0 absorbable suture (Vicryl).
 - ◆ Use the largest malecot catheter available.
 - Bring up a Roux-en-Y jejunal limb and create an anastomosis between the limb and the injury (Fig. 17-7).
 - The procedure of last resort is pancreaticoduodenectomy.

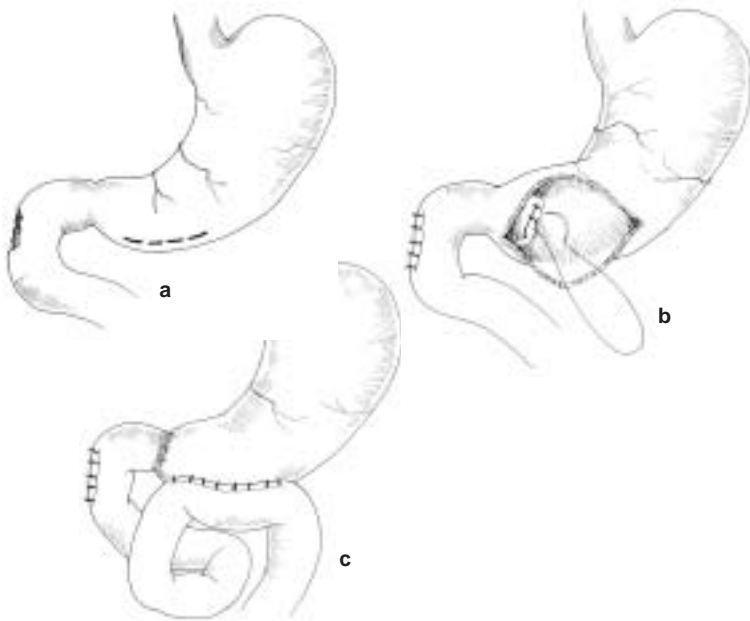


Fig. 17-7. (a) Ligation of pylorus, (b) Duodenal injury, (c) Roux-en-Y anastomosis.

- For major injuries, divert the gastric stream with a gastrostomy and close the pylorus—two options:
 - Through a gastrostomy, ligate the pylorus with No. 0 absorbable suture.
 - Using a noncutting stapling device, staple but **do not divide** the pylorus. Place a feeding jejunostomy for nutrition at this controlled reconstruction.
- Widely drain all injuries with closed-suction drains.
- Any method used to close the pylorus will last only 14–21 days. The possibility of injury to the biliary and pancreatic ducts should be considered when injuries involve the 2nd portion of the duodenum or the pancreatic head.

Pancreas Injuries

- Any injury to the pancreas/duct requires drainage.

- o Even if ductal injury is not identified, it should be presumed and drained.
- o Resect clearly nonviable pancreatic body / tail tissue.
- Transection or near-transection of the pancreatic duct can be treated by
 - o Distal end of proximal pancreas segment oversewn / stapled.
 - o Proximal end of distal segment oversewn / stapled and entire distal segment left in-situ.
 - o Distal segment resection (typically requires splenectomy).
 - o Distal segment drainage by Roux-en-Y anastomosis to small bowel.

Major injuries to the head of the pancreas may require pancreaticoduodenectomy, which SHOULD NEVER BE ATTEMPTED in an austere environment but instead treated by the principles of damage control surgery—DRAIN, DRAIN, DRAIN.

Liver Injuries

- Most liver injuries can be successfully treated with direct pressure and packing followed by aggressive resuscitation and correction of coagulopathy.
- Generous exposure is required and should be gained early and aggressively.
 - o Mobilize triangular and coronary ligaments for full exposure
 - o Use extension into right chest if needed.
 - o Place several laparotomy pads above the dome of the liver to displace it down into the field of view.
- Short duration clamping of hepatic artery and portal vein (Pringle maneuver) may be required to slow bleeding while gaining other control. If bleeding continues despite Pringle maneuver, especially from behind the liver, this indicates a retrohepatic venous injury or retrohepatic vena caval injury. The injuries should be approached in only the most advanced settings with extraordinary amounts of resources. On table triage or aggressive packing and intensive care unit (ICU) resuscitation should be employed.
- Use finger fracture of liver parenchyma to expose deep bleeding vessels.

- Large exposed injuries of the liver parenchyma can be controlled in a number of ways:
 - Exposed large vessels and ducts should be suture-ligated.
 - Overlapping mattress sutures of No. 0-Chromic on a blunt liver needle is fast and effective for controlling raw surface bleeding.
 - Placement of Surgicel on the raw surface and high-power electrocautery to “weld” it in place is also effective.
- Bleeding tracts through the liver can be controlled by tying off the end of a Penrose drain, placing it through the tract, and “inflating” it with saline to tamponade the tract.
- Urgent surgical resection is **strongly discouraged**:
 - Indicated only when packing/pressure fails.
 - Follows functional or injury pattern, not anatomic lines.
- Use a pedicle of omentum in a large defect to reduce dead space.

Avoidance of coagulopathy, hypothermia and acidosis is essential in successful management of major liver injuries. APPLY DAMAGE CONTROL TECHNIQUES EARLY.

- Retrohepatic vena cava and hepatic vein injuries require a tremendous amount of resources (blood products, OR time, equipment) typically unavailable in a forward surgery setting (on-table triage in mass casualty).
 - Packing is most successful option.
 - If packing fails, consider an atrio-caval shunt. (see Figure 17-8).
- Provide generous closed suction drainage around major liver injuries.

Biliary Tract Injuries

- Injuries to the gall bladder are treated by cholecystectomy.
- Repair common bile duct injuries over a T-tube.

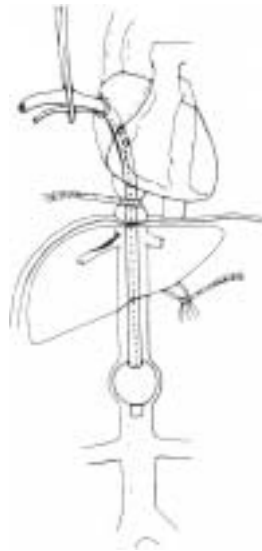


Fig. 17-8. Atrio-caval shunt.

- o A No. 4-0 or smaller absorbable suture is used on the biliary tree.
- Extensive segmental loss requires choledochoenterostomy or tube choledochostomy (depending on time and patient physiology).
- Drain widely.

Splenic Injuries

- Splenic salvage has no place in combat surgery.
- Drains should not be routinely placed postsplenectomy if the pancreas is uninvolved.
- Splenic injury should prompt exploration for associated diaphragm, stomach, pancreatic, and renal injuries.
- Immunize post-op with pneumococcal, haemophilus, and meningococcal vaccines (may defer until Level 3/CONUS MTF, **but must not be forgotten**).

Small-Bowel Injuries

- Debride wound edges to freshly bleeding tissue.
- Close enterotomies in one or two layers (skin stapler is a rapid alternative).
- With multiple enterotomies to one segment of less than 50% of small-bowel length, perform single resection with primary anastomosis. Avoid multiple resections.

Colon Injury

Simple, isolated colon injuries are uncommon. In indigenous populations and enemy combatants (eg, patients who cannot be readily evacuated), diversion with colostomy should be the procedure of choice, especially at Level 2. The often poor nutritional status of these populations does not support primary repair. The presence of any of the complicating factors listed below mandates colostomy.

- Simple, isolated colon injuries should be repaired primarily.
 - o Debride wound edges to normal, noncontused tissue.
 - o Perform two-layer closure or anastomosis.
- For **complex** injuries, **strongly consider colostomy/diversion**, especially when associated with:
 - o Massive blood transfusion requirement.
 - o On-going hypotension.
 - o Hypoxia (severe pulmonary injury).

- o Reperfusion injury (vascular injury).
- o Multiple other injuries.
- o High-velocity injuries.
- o Extensive local tissue damage.
- Potential breakdown of a repair or anastomosis is highest in the setting of concomitant pancreatic injury.
- Damage control technique: control contamination with ligation/ stapling of bowel, delay creation of the stoma to the definitive reconstruction.
- Clearly document treatment for optimal follow-up throughout Levels of Care.
- At the time of formation, a colostomy should be matured.

Rectal Injuries

Rectal injuries can be difficult to diagnose unless very dramatic. Any question of an injury raised by proximity of another injury, rectal examination, or plain abdominal film radiography **MANDATES** proctoscopy. Gentle distal washout with dilute Betadine solution is usually required to be able to perform rigid proctoscopy. Findings can be dramatic disruptions of the rectal wall but more commonly are subtle punctuate hemorrhages of the mucosa. All abnormal findings should prompt corrective intervention.

- Consider the traditional 4 “Ds” of rectal injury: **D**iversion, **D**ebriement, **D**istal washout, and **D**rainage.
 - o Of these, diversion is the most important.
 - ◆ Transabdominal sigmoid colostomy is easiest.
 - ◆ If the injury has not violated the peritoneum, exploration of the extraperitoneal rectum should **NOT** be done at laparotomy unless indicated for an associated nonbowel injury. This avoids contaminating the abdominal cavity with stool.
 - o Debridement and closure of small- to medium-sized wounds is unnecessary in patients who have been diverted and drained. In any but the lowest of wounds, debridement and closure are difficult and troublesome.
 - o Distal washout is usually necessary to assess the injury. Use gentle pressure when irrigating to minimize contamination of the perirectal space.

- o Fecal contamination of the perirectal space mandates presacral drainage. Presacral drains should be placed any time the patient will leave your immediate care.
 - ◆ Drains are placed through the perineum into the retrorectal space (Fig. 17-9).
- Peritonealized rectal injuries are easily accessed transabdominally and should be repaired and protected with diversion.
- Hematoma in the perirectal space should be drained either transluminally by leaving the injury open or by placing presacral and/or intraabdominal drains.

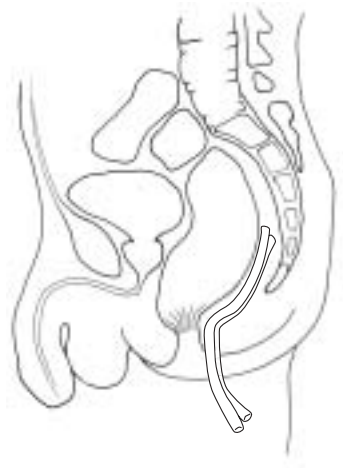


Fig. 17-9. Presacral drain.

Retroperitoneal Injuries

- Left medial visceral rotation moves the colon, pancreas, and small bowel to expose the aorta rapidly. Proximal aortic control can be rapidly obtained with compression or a clamp on the aorta at the hiatus, or through the left chest.
- Right medial visceral rotation (colon plus Kocher maneuver to elevate duodenum) exposes the subhepatic vena cava.
- Three zones of the retroperitoneum (Fig. 17-10).
 - o **I-Central, supracolic:** explore for all injuries.
 - o **II-Central, infracolic:** penetrating trauma, explore; blunt trauma, explore for expanding hematoma.
 - o **III-Lateral:** blunt trauma, avoid exploration if possible because exploration increases the likelihood of opening a stable hematoma and, thus, precipitating nephrectomy. Explore for penetrating trauma.
- Gain proximal vascular control before entering the hematoma.

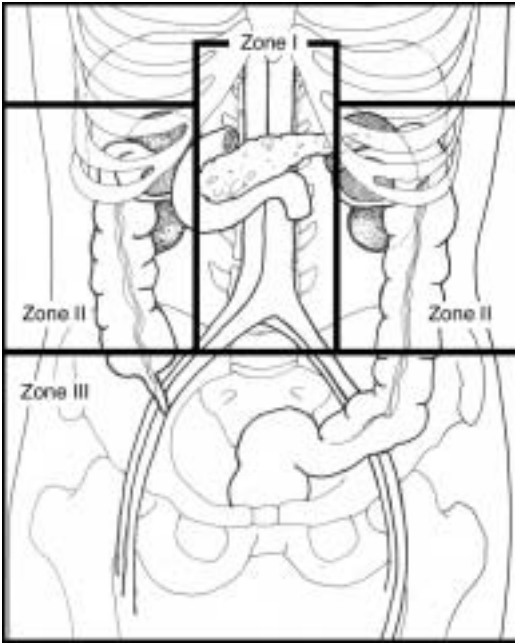


Fig. 17-10. Three zones of the retroperitoneum.

Abdominal Closure

- Close fascia if possible.
 - Massive swelling associated with large amounts of blood loss and resuscitation and large injuries may necessitate temporary closures (see Chapter 12, Damage Control Surgery). Otherwise, closure is usually possible.
- A few penetrating battlefield wounds are isolated, small, and without visceral contamination, and it is perhaps safe to close the skin. **Most are not, and these patients will be passed quickly from one surgeon to the next, so the risk of missed and catastrophic infection is increased; the skin should not be closed.**
- Retention sutures are strongly recommended for the same reasons.