

## Chapter 14

# Ocular Injuries

### Introduction

The preservation of the eyes and eyesight of service personnel is an extremely important goal. Despite comprising as little as 0.1% of the total body surface area, injuries to the eye are found in 5–10% of all combat casualties. In the Vietnam War almost 50% of casualties with penetrating eye wounds eventually lost vision in the injured eye. Improvements in ophthalmic care in the last 30 years offer hope that blindness in combat casualties will be less common in future wars.

### Triage of Patients With Eye Injuries

- ABCs (airway, breathing, and circulation) and life-threatening injuries have priority, then treat eyesight and limbs.
- Soldiers with mild eye injuries may be treated and returned to duty by nonspecialized personnel.
- Soldiers with more severe injuries should be evacuated to save vision.
- Distinguishing major ocular injuries from minor ones may be difficult.
- At the FST level, due to time and equipment restraints, surgeons will likely ‘patch and evacuate’.

### Identifying Severe Eye Injuries

- Associated injuries.
  - Shrapnel wounds of the face — think intraocular foreign body (IOFB).
  - Lid laceration — check for underlying globe laceration.
- Vision.

- o Use book print, medication labels, finger counting, and the like, to evaluate vision.
- o Compare sight in the injured eye to the uninjured eye.
- o Severe vision loss is a strong indicator of serious injury.
- Eyeball structure.
  - o Obvious corneal or scleral lacerations.
  - o Subconjunctival hemorrhage — may overlay an open globe.
  - o Dark uveal tissue presenting on the surface of the eye indicates an open globe.
  - o Foreign body — did it penetrate the eye?
  - o Blood in the anterior chamber (hyphema) indicates severe blunt trauma or penetrating trauma.
- Proptosis — may indicate a retrobulbar hemorrhage.
- Pupils.
  - o Pupillary distortion — may be associated with an open globe.
- Motility.
  - o Decreased motility on one side may be caused by an open globe.
  - o Other causes include muscle injury, orbital fracture, and orbital hemorrhage.

### **Open Globe**

- May result from penetrating or blunt eye trauma.
- May cause loss of vision from either disruption of ocular structures or secondary infection (endophthalmitis).
- Biplanar radiographs or a CT (computed tomography) scan of the head may help to identify a metallic intraocular fragment in a casualty with severe vision loss, a traumatic hyphema, a large subconjunctival hemorrhage, or other signs suspicious for an open globe with an IOFB.

### **Immediate Treatment of an Open Globe**

- Tape a rigid eye shield (NOT a pressure patch) over the eye.
- Do not apply pressure on or manipulate the eye.
- Do not apply any topical medications.
- Start quinolone antibiotic PO or IV (eg, ciprofloxacin 500 mg bid).

- Schedule an urgent (within 24–48 h) referral to an ophthalmologist.
- Administer tetanus toxoid if indicated.
- Prevent emesis (Phenergan 50 mg or Compazine 10 mg IM/IV).

### **Treatment of Other Anterior Segment Injuries**

#### **Subconjunctival Hemorrhage**

- Small subconjunctival hemorrhages (SCH) may occur spontaneously or in association with blunt trauma. These lesions require no treatment.
- SCH may also occur in association with a rupture of the underlying sclera.
- Warning signs for an open globe include a large SCH with chemosis (conjunctiva bulging away from globe) in the setting of blunt trauma, or **any** SCH in the setting of penetrating injury. Casualties with blast injury and normal vision do not require special care.
- Suspected open globe patients should be treated as described above.

#### **Treatment of Chemical Injuries of the Cornea**

- Immediate copious irrigation (for 30 minutes) with normal saline (NS), lactated Ringer's (LR), or balanced salt solution.
- Nonsterile water may be used if it is the only liquid available.
- Use topical anesthesia before irrigating, if available.
- Measure the pH of tears to ensure that if there is either acid or alkali in the eye, the irrigation continues until the pH returns to normal. Do not use alkaline solutions to neutralize acidity or vice versa.
- Remove any retained particles.
- Using fluorescein test, look for epithelial defect.
  - If none, then mild chemical injuries or foreign bodies may be treated with artificial tears.
  - If an epithelial defect is present, use a broad-spectrum antibiotic ophthalmic ointment (Polysporin, erythromycin, or bacitracin) 4 times per day.
- Noncaustic chemical injuries usually resolve without sequelae.

- More severe chemical injuries may also require treatment with prednisolone 1% drops 4–9 times per day and scopolamine 0.25% drops 2–4 times per day.
- Pressure patch between drops or ointment if a large epithelial defect is present.
- Monitor (daily topical fluorescein evaluation) for a corneal ulcer until epithelial healing is complete.
- Severe acid or alkali injuries of the eye (recognized by pronounced chemosis, limbal blanching, and/or corneal opacification) can lead to infection of the cornea, glaucoma, and possible loss of the eye. Refer to an ophthalmologist within 24–48 hours.
- Treat mustard eye injuries with ophthalmic ointments, such as 5% boric acid ointment, to provide lubrication and minimal antibacterial effects. Apply sterile petrolatum jelly between the eyelids to provide additional lubrication and prevent sealing of the eyelids.
- Treat nerve agent ocular symptoms with 1% atropine sulfate ophthalmic ointment, repeat as needed at intervals of several hours for 1–3 days.

### **Corneal Abrasions**

- Diagnosis.
  - Be alert for the possibility of an associated open globe.
  - The eye is usually very symptomatic with pain, tearing, and photophobia.
  - Vision may be diminished from the abrasion itself or from the profuse tearing.
  - Diagnose with topical fluorescein and cobalt blue light (Wood's lamp).
  - A topical anesthetic may be used for diagnosis, but should NOT be used as an ongoing analgesic agent — this delays healing and may cause other complications.
- Treatment.
  - Apply broad spectrum antibiotic ointment (Polysporin, erythromycin, or bacitracin) qid.
  - Options for pain relief.
    - ◆ Pressure patch (usually sufficient for most abrasions).
    - ◆ Diclofenac 0.1% drops qid.

- ◆ Larger abrasions may require a mild cycloplegic agent (1% Mydracil or Cyclogyl) and a pressure patch.
- ◆ More severe discomfort can be treated with 0.25% scopolamine one drop bid, but this will result in pupil dilation and blurred vision for 5–6 days.
- Small abrasions usually heal well without patching.
- If the eye is not patched
  - ◆ Antibiotic drops (fluoroquinolone or aminoglycoside) may be used qid in lieu of ointment.
  - ◆ Sunglasses are helpful in reducing photophobia.
- Casualties who wear contact lenses should have the lens removed and should not be treated with a patch because of the higher risk of developing a bacterial corneal ulcer.
- Abrasions will normally heal in 1–4 days.
- Initial treatment of thermal burns of the cornea is similar to that for corneal abrasions.

**All corneal abrasions need to be checked once a day until healing is complete to ensure that the abrasion has not been complicated by secondary infection (corneal ulcer, bacterial keratitis).**

### Corneal Ulcer and Bacterial Keratitis

- Diagnosis.
  - **Corneal ulcer and bacteria keratitis are serious conditions that may cause loss of vision or even loss of the eye!**
  - A history of corneal abrasion or contact lens wear.
  - Increasing pain and redness.
  - Decreasing vision.
  - Persistent or increasing epithelial defect (positive fluorescein test).
  - White or gray spot on the cornea seen on examination with penlight or direct ophthalmoscope.
- Treatment.
  - Quinolone drops (eg, Ocuflax), 1 drop every 5 minutes for 5 doses initially, then 1 drop every 30 minutes for 6 hours, then 1 drop hourly around the clock thereafter.
  - Scopolamine 0.25%, one drop bid may help relieve discomfort caused by ciliary spasm.

- o Patching and use of topical anesthetics for pain control are contraindicated (see pain control measures above).
- o Expedited referral to an ophthalmologist within 3–5 days unless patient is not improving within 48 hours. Infection may worsen, leading to permanent injury.

### **Conjunctival and Corneal Foreign Bodies**

- **Diagnosis.**
  - o Abrupt onset of discomfort and/or history of suspected foreign body.
  - o If an open globe is suspect, treat as discussed above.
  - o Definitive diagnosis requires visualization of the offending object, which may sometimes be quite difficult.
    - ◆ A hand-held magnifying lens or pair of reading glasses will provide magnification to aid in the visualization of the foreign body.
    - ◆ Stain the eye with fluorescein to check for a corneal abrasion.
  - o The casualty may be able to help with localization if asked to indicate the perceived location of the foreign body prior to instillation of topical anesthesia.
  - o Eyelid eversion with a cotton-tipped applicator helps the examiner identify foreign bodies located on the upper tarsal plate.
- **Treatment.**
  - o Superficial conjunctival or corneal foreign bodies may be irrigated away or removed with a moistened sterile swab under topical anesthesia.
  - o Objects adherent to the cornea may be removed with a spud or a sterile 22-gauge hypodermic needle mounted on a tuberculin syringe (hold the needle **tangential** to the eye).
  - o If no foreign body is visualized, but the index of suspicion is high, vigorous irrigation with artificial tears or sweeps of the conjunctival fornices with a moistened cotton-tipped applicator after topical anesthesia may be successful in removing the foreign body.
  - o If an epithelial defect is present after removal of the foreign body, treat as discussed above for a corneal abrasion.

### **Hyphema: Blood in the Anterior Chamber**

- Treatment (to prevent vision loss from increased intraocular pressure).
  - Be alert for a possible open globe and treat for that condition if suspected.
  - Avoidance of rebleeds is a major goal of management.
    - ◆ **Avoid** aspirin or nonsteroidal antiinflammatory drugs (NSAID).
    - ◆ No strenuous activity (bedrest) for 14 days.
    - ◆ No reading for 7 days.
  - Prednisolone 1% drops 4 times a day.
  - Scopolamine 0.25% drops twice a day.
  - Cover eye with protective shield.
  - Elevate head of bed to promote settling of red blood cells (RBC) in anterior chamber.
  - Provide a 24–48 hour referral to an ophthalmologist to monitor for increased intraocular pressure (which may cause permanent injury to the optic nerve) and to evaluate for an associated open globe.
  - If evaluation by an ophthalmologist is delayed (> 24 hrs), treat with a topical B-blocker (timolol or levobunolol) bid to help prevent intraocular pressure elevation.
  - If intraocular pressure is found to be markedly elevated (above 30 mm Hg) with a tonopen or other portable tonometry device, other options for lowering intraocular pressure include acetazolamide 500 mg PO or IV and mannitol 1–2 g/kg IV over 45 minutes.

### **Retrobulbar (Orbital) Hemorrhage**

- Keys to recognition: Severe eye pain, proptosis, vision loss, decreased eye movement.
  - Marked lid edema may make the proptosis difficult to appreciate.
  - Failure to recognize may result in blindness from increased ocular pressure.
- Perform an immediate lateral canthotomy.
- Provide an urgent referral to an ophthalmologist, within 24–48 hours.

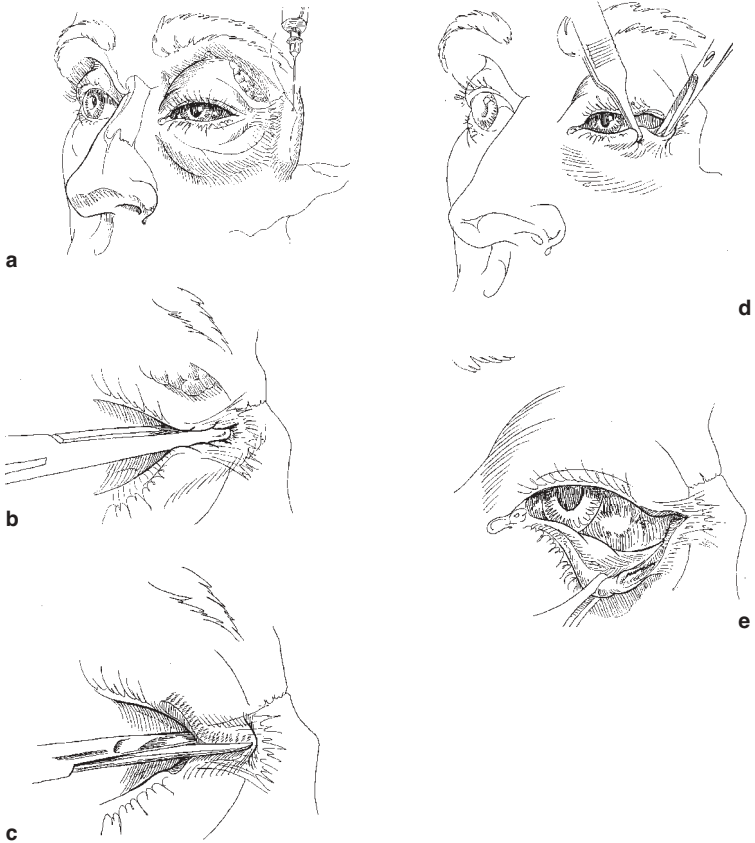
- If evaluation by an ophthalmologist is delayed (>24 hrs), treat with a topical B-blocker (timolol) bid to help lower intraocular pressure elevation.
- If intraocular pressure is found to be elevated (>30 mm Hg), treat as discussed above.

### **Lateral Canthotomy/Cantholysis**

Do not perform such procedures if the eyeball structure has been violated. If the eye is sliced open, apply a Fox shield for protection and seek immediate ophthalmic surgical support.

- Inject 2% lidocaine with 1:100,000 epinephrine into the lateral canthus (Fig. 14-1a).
- Crush the lateral canthus with a straight hemostat, advancing the jaws to the lateral fornix (Fig. 14-1b).
- Using straight scissors make a 1-cm long horizontal incision of the later canthal tendon, in the middle of the crush mark (Fig. 14-1c).
- Grasp the lower eyelid with large toothed forceps pulling the eyelid away from the face. This pulls the inferior crus (band of the lateral canthal tendon) tight so it can be easily cut loose from the orbital rim (Fig.14-1d).
  - Use blunt tipped scissors to cut the inferior crus.
  - Keep the scissors parallel (flat) to the face with the tips pointing toward the chin.
  - Place the inner blade just anterior to the conjunctiva and the outer blade just deep to the skin.
  - The eyelid should pull freely away from the face, releasing pressure on the globe.
  - Cut residual lateral attachments of the lower eyelid if it does not move freely.
  - Do not worry about cutting  $1/2$  cm of conjunctiva or skin.
  - The lower eyelid is cut, relieving orbital pressure. If the intact cornea is exposed, apply, hourly, copious erythromycin ophthalmic ointment or ophthalmic lubricant ointment to prevent devastating corneal dessication and infection. Relief of orbital pressure must be followed by lubricating protection of the cornea and urgent ophthalmic surgical support. Do NOT apply absorbent gauze dressings to the exposed cornea.





**Fig. 14-1.** Lateral canthotomy and inferior cantholysis are indicated for casualties presenting with serious orbital hemorrhage.

### **Orbital Floor (Blowout) Fractures**

These fractures are usually the result of a blunt injury to the globe or orbital rim, often associated with head and spine injuries. Blowout fractures may be suspected on the basis of enophthalmos, diplopia, decreased ocular motility, hypoesthesia of the V2 branch of the trigeminal nerve, associated subconjunctival hemorrhage, or hyphema. Immediate treatment includes pseudoephedrine 60 mg q 6 hours and a broad-

spectrum antibiotic for 7 days, ice packs, and instructing the casualty not to blow his nose. Definitive diagnosis requires CT scan of orbits with axial and coronal views. Indications for repair include severe enophthalmos and diplopia in the primary or reading gaze positions. The surgery may be performed 1–2 weeks after the injury.

## **Lid Lacerations**

### **Treatment guidelines for lid lacerations not involving the lid margin**

- Excellent blood supply — delayed primary closure is not necessary.
- Eyelid function (protecting the globe) is the primary consideration.
- Begin with irrigation, antisepsis (any topical solution), and a check for retained foreign bodies.
- Superficial lacerations of the eyelid, not involving the eyelid margin, may be closed with running or interrupted 6-0 silk (preferred) or nylon sutures.
- Horizontal lacerations should include the orbicular muscle and skin in the repair.
- If skin is missing, an advancement flap may be created to fill in the defect. For vertical or stellate lacerations, use traction sutures in the eyelid margin for 7–10 days.
- Antibiotic ointments qid.
- Skin sutures may be removed in 5 days.

### **Treatment guidelines for lid lacerations involving the lid margin**

- Repair of a marginal lower-eyelid laceration with less than 25% tissue loss (Fig. 14-2).
  - The irregular laceration edges may be freshened by creating a pentagonal wedge — remove as little tissue as possible (Fig. 14-2b).
  - A 4-0 silk or nylon suture is placed in the eyelid margin (through the meibomian gland orifices 2 mm from the wound edges and 2 mm deep) and is tied in a slipknot. Symmetric suture placement is critical to obtain post-op eyelid margin alignment (Fig. 14-2c).

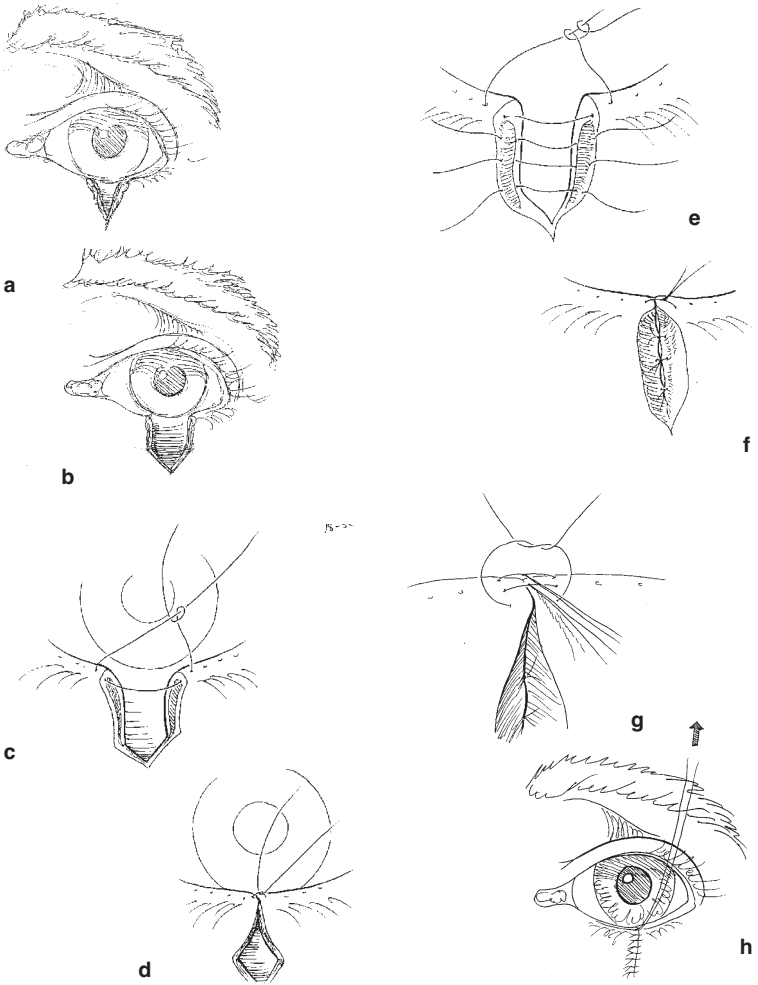


Fig. 14-2. Lid margin repair.

- o The slipknot is loosened and approximately two or three absorbable (Vicryl or gut) 5-0 or 6-0 sutures are placed internally to approximate the tarsal plate. The skin and conjunctiva should not be included in this internal closure (Fig. 14-2d).

- o Anterior and posterior marginal sutures (6-0 silk or nylon) are placed in the eyelid margin just in front and behind the previously placed 4-0 suture (Fig. 14-2e).
- o The middle and posterior sutures are left long and tied under the anterior suture. Ensure that the wound edges are everted (Fig. 14-2f).
- o The skin is closed with 6-0 silk or nylon sutures. The lid is placed on traction for at least 5 days. The skin sutures are removed at 3–5 days and the marginal sutures are removed at 10–14 days (Fig. 14-2g).

### **Additional Points in Lid Laceration Repair**

- Tissue loss greater than 25% will require a flap or graft.
- If there is orbital fat in the wound or if ptosis is noted in an upper lid laceration, damage to the orbital septum and the levator aponeurosis should be suspected.
- If the eyelid is avulsed, the missing tissue should be retrieved, wrapped in moistened Telfa, and preserved on ice. The tissue should be soaked in a dilute antibiotic solution prior to reattachment. If necrosis is present, minimal debridement should occur in order to prevent further tissue loss. The avulsed tissue should be secured in the anatomically correct position in the manner described for lid margin repair above.
  - o Damage to the canalicular system can occur as a result of injuries to the medial aspect of the lid margins. Suspected canalicular injuries should be repaired by an ophthalmologist to prevent subsequent problems with tear drainage. This repair can be delayed for up to 24 hours.

### **Laser Eye Injuries**

- Battlefield lasers may be designed to cause eye injuries or may be part of other weapons or sensor systems.
- **Prevention is the best option!** Wear eye protection designed for the appropriate light wavelengths if there is a known laser threat.
- The type of ocular damage depends on the wavelength of the laser — retinal injuries are most common.

- The primary symptom of laser injury is loss of vision, which may be preceded by seeing a flash of light. Pain may not be present.
- Immediate treatment of corneal laser burns is similar to that for corneal abrasions.
- Laser retinal burns have no proven immediate treatment, although improvement with corticosteroids has been reported.
- Routine evacuation for evaluation by an ophthalmologist is required.

### **Enucleation**

A general surgeon in a forward unit should not remove a traumatized eye unless the globe is completely disorganized. Enucleation should only be considered if the patient has a very severe injury, no light perception using the brightest light source available, and is not able to be evacuated to a facility with an ophthalmologist. Sympathetic ophthalmia is a condition that may result in loss of vision in the fellow eye if a severely traumatized, nonseeing eye is not removed, but it rarely develops prior to 21 days after an injury. **Delaying the enucleation until the patient can see an ophthalmologist is thus relatively safe.**

