

# Face and Neck Injuries

## Introduction

**Immediate recognition and appropriate management of airway compromise is critical to survival.**

- Face and neck injuries can be the most difficult-to-manage wounds encountered by health care providers in the combat zone. **Focusing on ABC priorities is vital.**
- During **airway** control, maintain cervical spine immobilization in bluntly injured patients. (Unstable C-spine injury is very rare in neurologically intact penetrating face and neck wounds.)
- **Bleeding** should be initially controlled with direct pressure. If bleeding cannot be controlled, immediate operative intervention is necessary.
- **Complete assessment** of remaining injuries (fractures, lacerations, esophageal injury, ocular injuries).

## Immediate Management of Facial Injuries

- Airway.
  - Airway distress due to upper airway obstruction above the vocal cords is generally marked by inspiratory stridor:
    - ◆ Blood or edema resulting from the injury.
    - ◆ Tongue may obstruct the airway in a patient with a mandible fracture.
    - ◆ A fractured, free-floating maxilla can fall back, obstructing the airway.
    - ◆ Displaced tooth fragments may also become foreign bodies.
  - Maneuvers to relieve upper airway obstruction:

- ◆ Remove foreign bodies (strong suction, Magill forceps, among others).
- ◆ Anterior jaw-thrust maneuver.
- ◆ Place adjunctive airway device (nasal trumpet or oropharyngeal airway).
- ◆ Endotracheal intubation and assisted ventilation.
- ◆ Cricothyroidotomy or emergent tracheotomy may become necessary.
- Cervical spine.
  - Up to 10% of patients with significant blunt facial injuries will also have a C-spine injury.
    - ◆ In awake patients, the C-spine can be cleared clinically by palpating for point tenderness.
    - ◆ Obtunded patients with blunt facial trauma should be treated with C-spine immobilization.
- **Vascular Injury.**
  - Injuries to the face are often accompanied by **significant bleeding**.
  - Control of facial vascular injuries should progress from simple wound compression for mild bleeding to vessel ligation for significant bleeding.

**Vessel ligation should only be performed under direct visualization after careful identification of the bleeding vessel. Blind clamping of bleeding areas should be avoided, because critical structures such as the facial nerve and parotid duct are susceptible to injury.**

- ◆ Foley catheter inserted blindly into a wound may rapidly staunch bleeding.
- Intraoral bleeding must be controlled to ensure a patent and safe airway.
  - ◆ Do not pack the oropharynx in an awake patient due to risk of airway compromise: first secure the airway with an endotracheal tube.
  - ◆ Copious irrigation and antibiotics with gram-positive coverage should be used liberally for penetrating injuries of the face.

- Evaluation.
  - Once the casualty is stabilized, cleanse dried blood and foreign bodies gently from wound sites in order to evaluate the depth and extent of injury.
  - The bony orbits, maxilla, forehead, and mandible should be palpated for stepoffs or mobile segments suggestive of a fracture.
  - A complete intraoral examination includes inspection and palpation of all mucosal surfaces for lacerations, ecchymosis, stepoffs, and malocclusion as well as dental integrity.
  - **In the awake patient, abnormal dental occlusion indicates probable fracture.**
  - Perform a cranial nerve examination to assess vision, gross hearing, facial sensation, facial muscle movement, tongue mobility, extraocular movements, and to rule out entrapment of the globe.
  - Consult an ophthalmologist for decreased vision on gross visual field testing, diplopia, or decreased ocular mobility.
  - If the intercanthal distance measures  $> 40$  mm (approximately the width of the patient's eye), the patient should be evaluated and treated for a possible naso-orbito-ethmoid (NOE) fracture.
- If a NOE fracture is present, do not instrument the nose if possible. There may be a tear in the dura, and instrumentation may contaminate the CSF via the cribiform.

### Facial Bone Fracture Management

The goals of fracture repair are realignment and fixation of fragments in correct anatomic position with dental wire (inferior, but easier) or plates and screws.

**With the exception of fractures that significantly alter normal dental occlusion or compromise the airway (eg, mandible fractures), repair of facial fractures may be delayed for two weeks.**

- Fractures of the mandible.
  - Second most commonly fractured bone of the face.
  - Most often fractured in the subcondylar region.

- o Multiple mandible fracture sites present in 50% of cases.
- o Patients present with limited jaw mobility or malocclusion.
- o Dental Panorex is the single best plain film (but is unavailable in the field environment); mandible serves as a less reliable but satisfactory study (might overlook subcondylar fractures).
- o Fine cut (1–3 mm) CT scan will delineate mandibular fractures.
- o Treatment is determined by the location and severity of the fracture and condition of existing dentition.
  - ◆ Remove only teeth that are severely loose or fractured with exposed pulp.
  - ◆ Even teeth in the line of a fracture, if stable, and not impeding the occlusion, should be maintained.
- o Nondisplaced subcondylar fractures in patients with normal occlusion may be treated simply with a soft diet and limited wear of Kevlar helmet and protective mask.
- o Immediate reduction of the mandibular fracture and improvement of occlusion can be accomplished with a bridle wire (24 or 25 gauge) placed around at least 2 teeth on either side of the fracture.
- o More severe fractures with malocclusion will require immobilization with maxillary-mandibular fixation (MMF) for 6–7 weeks.
- o Place commercially made arch bars onto the facial aspect of the maxillary and mandibular teeth.
  - ◆ The arch-bars are then fixed to the teeth with simple circumdental (24 or 25 gauge) wires (Fig. 13-1).
  - ◆ After proper occlusion is established, the maxillary arch bar is fixed to the mandibular arch bar with either wire or elastics.
  - ◆ If the patient's jaws are wired together, it is imperative that **wire cutters be with the patient at all times.**
  - ◆ If portions of the mandible have been avulsed or the mandibular fragments are extremely contaminated, an external biphase splint should be placed to maintain alignment.

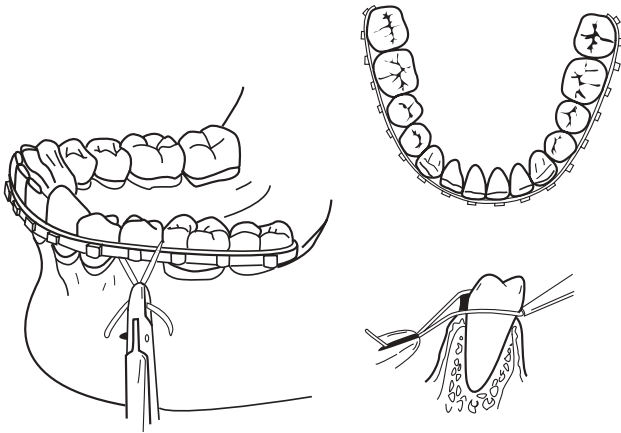


Fig. 13-1. Arch bar applications.

- o Open reduction and internal fixation with a mandibular plate across fracture sites may obviate the need for MMF.
- **Nasal fractures.**
  - o Most common fracture.
    - ◆ Control of epistaxis: anterior pack-gauze/balloon/tamponade.
  - o Diagnosed clinically by the appearance and mobility of the nasal bones.

**The patient's septum should be evaluated for the presence of a septal hematoma, which if present, must be immediately drained by incision, followed by packing.**

- o Treat by closed reduction of the fractured bones and/or septum into their correct anatomic positions up to 7 days after fracture.

- ◆ Place a blunt elevator (Sayer) into the nasal cavity in order to elevate the depressed bony segment while simultaneously repositioning the bone with the surgeon's thumb placed externally.
- o The nose may then be fixed with tape or a splint in order to maintain the reduction (Fig. 13-2).

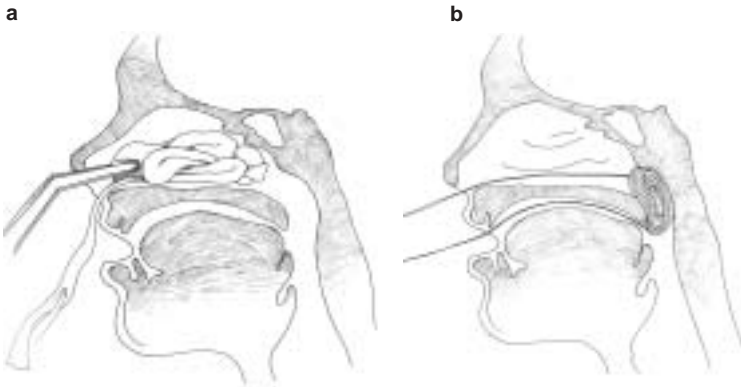


Fig. 13-2. (a) Anterior and (b) posterior packing of the nose.

● **Maxillofacial Trauma.**

- o Life-threatening due to loss of airway, hemorrhage, or spinal injury.
- o Fragment wound of maxillary sinus is commonly seen and requires surgical removal of retained fragments (can delay until specialist is available).
- **Bleeding.**
  - o Common from epistaxis, oral hemorrhage or combination bleeding.
  - o Nasal fracture—most common fracture.
    - ◆ Control Epistaxis with Anterior Pack (gauze/balloon/tampon).
  - o Mandibular fracture fixation (wires/archbars, **with wire cutters at bedside**).
  - o Facial and scalp lacerations.
  - o Mid-face fracture (Le Fort)—The most difficult bleeding to control.

- ◆ Requires “significant” trauma.
- ◆ Be aware of associated CNS and orbital injury.
- ◆ Significant hemorrhage due to laceration of IMA and branches.
  - ◇ Is difficult to control.
  - ◇ May be life-threatening.
  - ◇ Treat by controlling airway, reducing fracture, and placing a pressure dressing such as packing or balloon.
- ◆ Edema may cause loss of airway, which may be immediate or delayed.
- ◆ Can be difficult to diagnose. Criteria:
  - ◇ Mobile hard palate and mid-face while stabilizing the skull.
  - ◇ Penetrating injury may not follow classic Le Fort patterns but may have a significant soft tissue injury component (base of tongue, soft palate).
- Treatment.
  - ABCs.
  - Check CNS and vision.
  - Can immobilize maxilla by using the mandible as a splint (wires/archbars, **with wire cutters at bedside**).
  - Control hemorrhage by tamponade.
    - ◆ Nasopharynx, nasal cavity.
    - ◆ Oropharynx.
- Surgical Repair.
  - **Not an emergency** once hemorrhage is controlled.
  - Requires ENT, oral, plastic, and ophthalmology surgical expertise.
  - Time consuming.
  - Open and closed reductions with hardware that is usually unavailable in the field.
- Fractures of Facial Bones.
  - Potentially life-threatening due to loss of airway, hemorrhage, or spinal injury.
  - Fragment wound of maxillary sinus is commonly seen, and requires surgical removal of retained fragments (can delay until specialist available).
  - Mid-face fracture (Le Fort)—**The** most difficult bleeding to control.
    - ◆ Requires “significant” trauma.

- ◆ Be aware of associated CNS and orbital injury.
  - ◆ Significant hemorrhage due to laceration of IMA and branches.
    - ◇ Is difficult to control.
    - ◇ May be life threatening.
    - ◇ Treat by controlling the airway, reducing fractures, and placing pressure dressings such as packing or balloon tamponade.
  - ◆ Edema may cause loss of airway, which may be immediate or delayed.
  - ◆ Can be difficult to diagnose.
    - ◇ Mobilize the hard palate and mid-face while stabilizing the skull. Place thumb and forefinger of one hand on nasal bridge to stabilize, then with the other hand, determine mobility of maxilla by placing the thumb on alveolus and forefinger on the palate and attempting gentle distraction in an anterior-posterior direction.
    - ◇ Penetrating injury may not follow classic Le Fort patterns but may have a significant soft tissue injury component (base of tongue, soft palate).
    - ◇ Apply principles of systemic palpation and inspection, looking for crepitus, tenderness, internal and external ecchymosis, and subconjunctival hemorrhage that might suggest fractures.
- o Classification by Le Fort (Fig. 13-3).

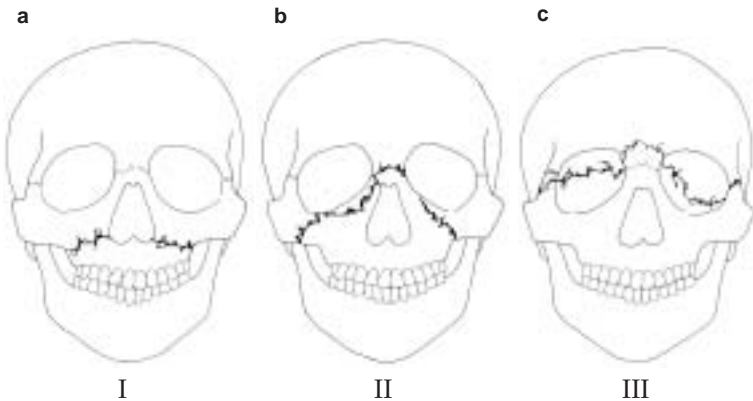


Fig. 13-3. Le Fort facial fracture classifications.



- ◆ I–Fracture separates the entire alveolar process from maxilla.
- ◆ II–Separation of mid-face, including the nasal bone, from the orbit (pyramidal).
- ◆ III–Detachment of the face from the skull (craniofacial disarticulation).
- o Treatment.
  - ◆ ABCs.
  - ◆ If nasal intubation is used, **extremely careful placement** is mandatory to avoid cribriform plate or anterior cranial fossa penetration.
  - ◆ Classification by Le Fort.
  - ◆ Check CNS and vision.
  - ◆ Can immobilize maxilla by using the mandible as a splint (wires/arch bars, **with wire cutters at bedside**). It is much easier to place patient into maxillomandibular fixation if either a nasal airway or tracheostomy is employed.
  - ◆ Control hemorrhage by tamponade as previously described.
    - ◇ Nasopharynx, nasal cavity.
    - ◇ Oropharynx.
- o Definitive Surgical Repair.
  - ◆ **Not an emergency** once hemorrhage is controlled.
  - ◆ Requires expertise in ENT, oral and maxillofacial, plastic, and ophthalmology surgery.
  - ◆ Time consuming.
  - ◆ Open and closed reductions require hardware usually unavailable in the field.

### Soft Tissue Injuries

#### ● General principles.

- o Avoid injury to surrounding structures such as the facial nerve or parotid duct.
- o Wounds should be gently cleansed with saline and light scrub solutions; foreign bodies should be meticulously cleaned from wounds prior to closure.
- o Sharply debride devascularized wound edges **minimally**.
- o **Facial lacerations should be closed in layers within 24 hours.**
  - ◆ Use 4-0 or 5-0 absorbable suture for subcutaneous/dermal layers.

- ◆ Use 5-0 or 6-0 nonabsorbable sutures on the skin of the face.
- ◆ Remove sutures in 5–7 days.
- **Facial nerve injuries.**
  - Carefully examine for facial nerve function in all **five** branches (Fig. 13-4).

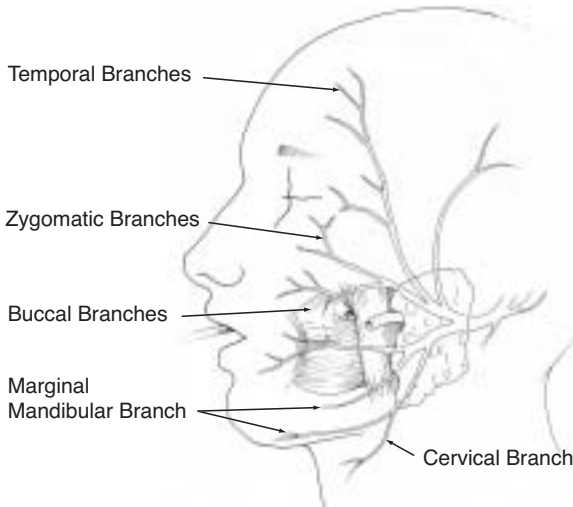


Fig. 13-4. Branches of the facial nerve parotid duct injury.

**Facial nerve branches that are lacerated at a site anterior to a vertical line drawn down from the lateral canthus of the eye do not need to be surgically reapproximated because these branches are very small and will spontaneously regenerate with good return of facial function.**

- The severed ends of the nerve may be located in the wound with a nerve stimulator, for up to 3 days.
- Cut nerve ends should be reapproximated primarily with three or four fine (9-0) nylon sutures placed through the epineurium.
- If a gap exists between severed ends of the facial nerve due to tissue loss, an interposition graft may be placed using a section of the great auricular nerve to bridge the gap.

- o If the wound is heavily contaminated and cannot be closed primarily, the severed ends of the nerve should be located and tagged for identification and repair at the time of wound closure.
- Parotid duct injuries.
  - o Evaluate penetrating wounds of the parotid/buccal regions of the face for salivary leakage due to a lacerated parotid duct (see Fig 13-5).
    - ◆ The wound may be manually compressed and inspected for salivary leakage.
    - ◆ If the parotid duct is injured by a facial laceration, the distal end of the duct may be identified by placing a lacrimal probe through the intraoral opening of the duct located near the maxillary second molar (see Fig. 13-4).
    - ◆ The proximal end may be identified by compressing the wound and identifying any areas of salivary leakage.
  - o Repair with absorbable (6-0) sutures (Fig. 13-5).



Fig. 13-5. Repair of parotid duct.

- o A stent may be placed into the duct to facilitate the closure and prevent stenosis.
  - ◆ Possible stents include lacrimal stents, large (size 0) polypropylene sutures, or long angiocaths.
  - ◆ Stents may be sutured to the buccal mucosa and removed after seven days.

## Penetrating Neck Trauma

- Introduction.

- Vascular injuries occur in 20% and aerodigestive tract in 10% of cases.
- Mortality is primarily due to exsanguinating hemorrhage.
- Esophageal injury, which results in mediastinitis and intractable sepsis, may also be fatal.

- **Anatomy.**

The neck is divided into three zones to aid decision making for diagnostic tests and surgical strategy. In each zone, the primary structures at risk of injury are different (Fig. 13-6).

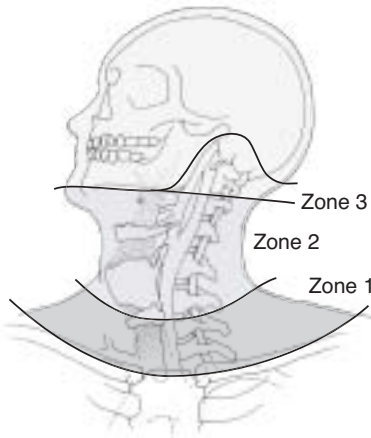


Fig. 13-6. Zones of the neck.

- Zone 1 (clavicle to cricoid membrane): The structures of concern include large vessels of the thoracic outlet (subclavian artery and vein, common carotid artery), the lung, and the brachial plexus.
- Zone 2 (cricoid membrane to angle of mandible): Structures of concern include the common carotid artery, internal jugular vein, esophagus, and trachea.
- Zone 3 (angle of mandible to base of skull): The structure of concern is primarily the internal carotid artery.

- Immediate management.
  - Initially, same as above.
  - Obtain chest and soft tissue neck radiographs.
  - Address tetanus and antibiotic prophylaxis.
- Operative strategy.
  - If no platysma violation, surgical intervention is not indicated.
  - Zone 2 injuries that penetrate the platysma should undergo routine exploration to rule out life threatening vascular, esophageal or tracheal injuries via an incision along the anterior border of the sternocleidomastoid muscle (Fig. 13-7).

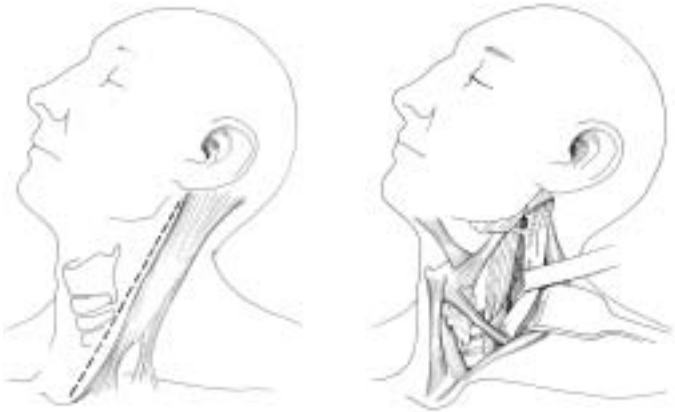


Fig. 13-7. Neck exposure of zone 2.

- Zone 1 and 3 injuries require selective management, based on clinical signs and chest radiograph findings, making an incision dependent on the vascular structure most probably injured.
  - ◆ Zone 1 and 3 penetrations without clinical signs of injury (see below) may be evacuated without operative intervention.
- The most important clinical signs pointing to probable injuries (pertinent to all 3 zones):

- ◆ Signs of vascular injury.
  - ◇ Current or history of significant bleeding.
  - ◇ Expanding hematoma.
  - ◇ Bruit or thrill in the neck.
  - ◇ Hypotension.
  - ◇ Dyspnea, hoarseness, or stridor.
  - ◇ Absent or decreased pulses in neck or arm.
  - ◇ Focal neurologic deficit or mental status change.
  - ◇ Chest radiograph findings of hemothorax or mediastinal widening.
- ◆ Signs of aerodigestive injury (esophagus, trachea, larynx).
  - ◇ Crepitus or subcutaneous emphysema.
  - ◇ Dyspnea or stridor.
  - ◇ Air bubbling from wound.
  - ◇ Tenderness or pain over trachea; odynophagia.
  - ◇ Hoarse or abnormal voice.
  - ◇ Hematemesis or hemoptysis.

### **Surgical Principles**

- The groin and upper thigh should be surgically prepped for greater saphenous vein interposition graft or patch angioplasty.
- Exsanguinating hemorrhage from injured vessels at the base of the skull (Zone 3) can often be controlled with inflation of a directed catheter (Fogarty, Foley), left in place and inflated for 48–72 hours, then deflated in the OR under controlled visualization for rebleeding.
- Repair esophageal injuries in a single-layer and place closed suction drains. The drain tip should not be placed near a concomitantly repaired carotid artery. A muscle flap should be interposed between repaired esophageal and tracheal injuries to prevent fistula. Obtain an oral contrast swallow radiograph seven days after repair before feeding.
- Repair laryngotracheal injuries with single-layer monofilament absorbable suture. Must search for concomitant esophageal injuries.
- Unreconstructable (significant segmental loss, or > 50% diameter loss) tracheal injuries should be managed with an endotracheal tube placed through the defect.

- **Vertebral artery injury.**
  - Suspect if bleeding continues from a posterolateral neck wound despite pressure on the carotid artery.
  - Preoperative angiography localizes site of injury and establishes the existence of a patent contralateral vertebral artery, aplasia of which is most commonly located on the left side.
  - Exposure of vertebral artery may be difficult. When contralateral vertebral artery is intact, ligation proximal and distal to the injury will likely be necessary.
  - Bone wax or a Foley catheter may be useful for control of bleeding.
- **Intraoral injuries**
  - Penetrating injuries to the oral cavity LATERAL to the tonsillar fossa are at a significant risk of causing occult internal carotid injury. Neurologic testing/monitoring is critical and CT scanning and/or angiography should be considered. If after a penetrating lateral oral injury the patient bleeds a small amount only to stop, this may signify a “sentinel” bleed. A carotid blowout may follow.
- **Internal carotid artery injury.**
  - Should be repaired primarily unless there is profound hemiplegia with deep coma Glasgow Coma Scale (GCS < 8). All other carotid branches can be ligated.
  - The use of carotid shunts during repair has no proven benefit.
  - In small perforations, debride minimally, and close with 6-0 polypropylene.
  - With loss of vascular tissue, vein angioplasty is required.
  - If there is extensive destruction, segmental resection and restitution of flow is established by:
    - ◆ End-to-end anastomosis (if the vessel is sufficiently elastic to permit).
    - ◆ Interposition vein graft.
    - ◆ External carotid swing-over and interposition.
    - ◆ Temporary (24–48 h) shunt as part of damage control maneuver.
  - The mortality is high in patients with severe neurologic deficit; carotid ligation is justifiable in complete occlusion of the entire carotid system and depending on the triage situation.
  - Distal clot may be removed by extremely gentle use of a balloon catheter prior to shunt insertion or repair.

- **Internal jugular vein injury.**
  - Preferably repaired by lateral suture.
  - Ligation OK, if the contralateral internal jugular is patent.
  - Larynx.
  - After immediate control of the airway has been achieved by intubation or tracheotomy (not through the wound in the larynx!), a complete airway evaluation by direct laryngoscopy and bronchoscopy must be performed.
  - Debridement of laryngotracheal injuries must be careful and conservative. A fragmented larynx or trachea should be reapproximated and sutured with extraluminal, absorbable sutures for tracheal injuries and nonabsorbable sutures or micro-plates used for laryngeal fractures.
  - The management of laryngeal trauma includes accurate reduction and stabilization of fractures, mucosa-to-mucosa closure of lacerations, and use of a soft stent if there is extensive cartilaginous damage and structural support is decreased or the anterior commissure is involved. The stent may need to be temporarily placed for 4–6 weeks to maintain correct anatomic architecture and requires a complementary tracheotomy.
  - The excessive removal of cartilage and mucosa must be avoided to prevent tracheal or laryngeal stenosis.
- **Laryngotracheal injuries.**
  - If laryngotracheal separation is suspected (massive crepitus over the larynx/trachea) in an otherwise “stable” airway, endotracheal intubation should not be undertaken as this may cause a partial separation to become a complete separation and/or blind passage of the endotracheal tube may occur with resulting impending airway emergency.
  - It is best to perform an awake tracheotomy/cricothyroidotomy under local anesthesia without paralysis. Good anesthesia can be achieved with a 4% (40mg/cc) lidocaine nebulizer, 2cc in 3cc of saline, and direct administration of 4% lidocaine into the trachea for an awake tracheotomy (in addition to local anesthetic infiltration into the skin and subcutaneous tissues). When instilling anesthesia into the airway, aspirate and ensure air enters the syringe before injecting.



- **Tracheal injury and reconstruction.**
  - Small anterior wounds can have tracheostomy tube placed through them after debridement.
  - Repair simple lacerations with absorbable monofilament suture.
  - Up to 5 cm can be resected with proximal and distal mobilization.
  - Mobilize anteriorly and posteriorly to preserve lateral blood supply.
  - Remove endotracheal tube as soon as possible post-op.
  - May need to suture chin to chest for 10 days to avoid extension injury.
- **Esophageal injury and repair.**
  - Difficult to diagnose.
  - 25% may be asymptomatic.
  - Missed injury is a major source of late morbidity / mortality.
  - Insufflation with air may aid in identification during exploration.
  - Debride devitalized tissue.
  - Wound closure in two layers with absorbable sutures.
  - Viable muscle flap to protect repairs from leak.
  - Drainage with closed suction drain.
  - Barium swallow 7 days post-op, prior to oral intake.
  - Oral intake prior to drain removal.
  - Extensive injuries may require lateral cervical esophagostomy.
  - Cervical esophagostomy is preferred to closure under tension.
- **Combined injuries.**
  - All esophageal injuries combined with airway or vascular injury require separation with healthy tissue. Strap muscles are ideal, but can use pedicle of sternocleidomastoid if straps are devitalized.
- **Esophageal fistula.**
  - 10%–30% incidence.
  - Due to inadequate debridement, devascularization of remaining esophageal wall, closure under tension, or infection.
  - Treatment.

- ◆ Maintain nutrition.
- ◆ Assure control with drains.
- ◆ Weekly barium swallow to assess closure.
- ◆ Oral intake prior to removing drain.

### **Skull Base, Temporal Bone and Otologic Injury**

- Ensure that the facial nerve is assessed and documented on an awake patient and at the earliest convenience in a patient who has regained consciousness. Delineation between delayed onset and acute facial paralysis is critical for management and outcome of facial nerve injuries. Also critical is delineation between a distal and proximal nerve injury. If a distal injury is present, one or more branches may be affected.
  - Be as concise as possible in describing facial motion even if not technically accurate; be complete in the description. A more proximal injury (proximal to the *Pes Anserinus*) will most likely result in all branches being equally affected. Accurate documentation may spare the patient from unwarranted surgical intervention to explore the entire length of the facial nerve. It is desirable to accurately describe the motion of EACH branch of the facial nerve. Eyelid movement does not ensure that the facial nerve is intact since the levator palpebrae is innervated by the oculomotor nerve and will remain intact despite facial nerve injury.
  - If there is no contraindication for systemic steroids, they should be administered for suspected facial nerve paralysis. Crush injuries to the facial nerve may present with delayed onset paralysis and the severity and course of the paresis may be improved with systemic administration of steroids.
- Skull base fractures are often occult. Assess the patient for evidence of basilar skull fractures (Battle's sign, raccoon eyes).
- Ensure that the external auditory canal is examined. Do not instrument the external auditory canal, however. If a temporal bone fracture is present and the dura is not intact, instrumentation may introduce bacteria and/or a foreign body into the CSF.

- The external auditory canal should be inspected for a tear of the lining of the canal. A tear of the lining of the canal suggests a temporal bone fracture.
  - If a temporal bone fracture is suspected, it is critical that the facial nerve be assessed.
- Tympanic membrane perforations can be managed expectantly. The vast majority of them will heal spontaneously, but the patient should be followed for evidence of cholesteatoma formation from traumatic implantation of the squamous epithelium. This may occur months to years after the injury. Acutely, application of otic antibiotic drops will prevent the perforation from desiccating, but this is not required. The patient should be instructed to keep the ears dry (avoid water contamination).
- Hemotympanum may be seen with acoustic & temporal bone trauma. These patients will have hearing loss. If available, perform a gross audiological evaluation with tuning forks. Hemotympanum with hearing loss (conductive) should resolve in about 6 weeks.
  - Examination for hearing in the field can be accomplished with a single 512 tuning fork.
    - ◆ With the tuning fork placed on the mastoid tip and then alternately in front of the external canal (Rinne). Documentation as A>B (air > bone) or B>A is sufficient – do not report as “positive” or “negative”:
      - ◇ Air conduction greater than bone conduction with a 512 tuning fork is normal.
      - ◇ Bone conduction greater than air is suggestive of a conductive hearing loss.
    - ◆ With the 512 tuning fork on the frontal bone/ nasal dorsum/ or central incisors (best) (Weber):
      - ◇ If the Rinne test suggests a conductive hearing loss – the 512 should lateralize to the side with the conductive loss.
      - ◇ If the Rinne is NORMAL (A>B) – the 512 should lateralize to the ear with a sensorineural loss
- Any otologic blast injury or injury to the temporal bone may result in tinnitus. Management is expectant and it may resolve

spontaneously. Accurate documentation is critical for future management of these patients, however.

- If sensorineural hearing loss is suspected and documented after a blast injury or noise trauma, steroids are indicated. 1mg/kg of prednisone is appropriate. If after five days there is no improvement, the patient can be taken off of the steroids. If improvement is noted, a taper over 3–4 weeks is indicated. Be mindful that steroids may affect a patient's affect and impair judgment.
- Dizziness and vertigo may result from acoustic trauma. If true vertigo exists after an otologic injury (observed nystagmus), the patient may have a perilymphatic fistula from depression of the stapes into the oval window or rupture of the round window. These patients may have tinnitus and hearing loss with vertigo. If a perilymphatic fistula is suspected, this patient should be seen by an Otolaryngologist as soon as possible to prevent further damage to the inner ear.